

Dislocation fracture of the femoral head in adult

Philippe Chiron¹ and Nicolas Reina

Orthopédie Traumatologie, Secteur A, Batiment riquet, étage 5, CHU Toulouse, Toulouse Cedex 9, France

Correspondence
should be addressed
to P Chiron
Email
desorthopedie@free.fr

- The smaller the head fragment, the more likely it is located at the bottom and in front of the femoral head, which then determines the most suitable approach.
- A CT scan is essential after reduction and before resumption of weight-bearing to verify the size and congruence of the fragments and whether there are foreign bodies and/or a fracture of the posterior wall.
- Classifications should include the size of the fragment and whether or not there is an associated fracture of the acetabulum or femoral neck (historical 'Pipkin', modernised 'Chiron').
- In an emergency, the dislocation should be rectified, without completing the fracture (sciatic nerve palsy should be diagnosed before reduction). A hip prosthesis may be indicated (age or associated cervical fracture).
- Delayed orthopaedic treatment is sufficient if congruence is good. A displaced fragment can be resected (foreign bodies and $\frac{1}{4}$ head), reduced and osteosynthesised ($\frac{1}{3}$ and $\frac{1}{2}$ head), and a posterior wall fracture reduced and osteosynthesised. Small fragments can be resected under arthroscopy. The approach is medial (Ludloff, Ferguson, Chiron) to remove or osteosynthesise $\frac{1}{3}$ or $\frac{1}{4}$ fragments; posterior for $\frac{1}{2}$ head or a fractured posterior wall.
- The results remain quite good in case of resection or an adequately reduced fragment. Long-term osteoarthritis is common (32%) but well tolerated with a low rate of prosthetisation. Avascular necrosis remains a possible complication (8.2%). Sciatic nerve palsy (4% of fracture dislocations) is more common for dislocations associated with posterior wall fractures.

Keywords

- ▶ femoral head fracture
- ▶ hip dislocation
- ▶ CT scan
- ▶ Pipkin
- ▶ Chiron
- ▶ medial approach
- ▶ herbert screws
- ▶ sciatic palsy

EFORT Open Reviews
(2022) 7, 375–383

Introduction

In most instances, fractures of the femoral head are the consequence of a high-energy trauma with posterior dislocation of the femoral head. A concomitant fracture of the posterior wall of the acetabulum is frequent. These fractures are relatively rare; the literature mainly reports isolated clinical cases; therefore, individual surgeons have limited experience. This review of the literature enables a better analysis of the type of fracture and the course of action in case of emergency or delayed treatment.

Pathomechanics

For posterior dislocations, fracture patterns depend on the position of the limb in the axis of the femur on a hip flexed to 90° during high-energy compression (dashboard injury). It is the degree of adduction and internal rotation of the lower limb that determines the position and size of the fragments, whether or not there is an associated posterior wall fracture and whether or not there is truncal or radicular paralysis:

- In forced adduction, internal rotation, the compressive forces are parallel to the posterior wall, the dislocation is pure or with small osteochondral fragments released from the inferior internal part of the femoral head (1) (Fig. 1).
- In neutral adduction (0°), the compressive forces are perpendicular to the posterior wall, the dislocation is associated with a fracture of a large suprafoveal femoral head fragment ($\frac{1}{2}$) with or without fracture of the posterior wall of the acetabulum (1) (Fig. 2).
- In intermediate rotational positions, dislocation is associated with fractures of $\frac{1}{4}$ (infrafoveal) or $\frac{1}{3}$ (suprafoveal) of the head which are located at the bottom and to the front; a posterior wall fracture could still occur (1) (Fig. 3).
- The sciatic nerve can be injured when there is an associated fracture of the posterior wall with a risk of truncal injury as a result of shearing by the detached wall fragment or radicular injury by traction of the nerve (1, 2, 3); the anatomy of the lumbar plexus and the path of the roots explain why the L5 root (external popliteal nerve (EPN)) is more sensitive to

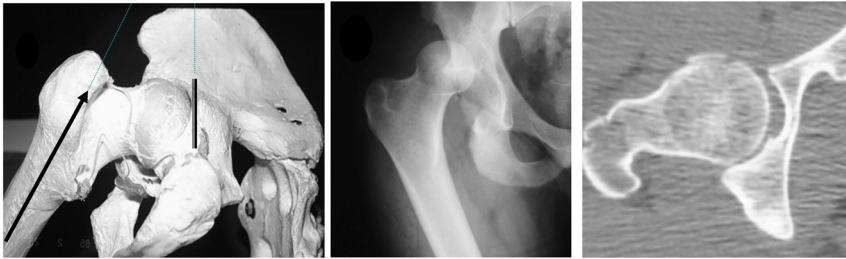


Figure 1
Mechanism of pure or foreign body dislocation.

stretching than the S1 root (internal popliteal nerve (IPN)) (2). For pure dislocations, the injury to the sciatic nerve may be truncal due to direct compression by the femoral head with ischaemia if reduction is delayed (1) or due to an injury by a fragment in the posterior wall (4, 5). In exceptional cases, the dislocation can be anterior or inferior (6, 7, 8); a femoral head fracture without dislocation could still occur (9).

Classifications

- Pipkin (1957) classification (Fig. 4)
This simple historical classification is still the most widely used. It describes forms of isolated femoral head fractures (infrafoveal fragment Type I or Type II – suprafoveal) or associated with a posterior wall fracture (Type III) or with a femoral neck fracture (Type IV) (10, 11). However, the size of the infrafoveal fragments is poorly determined; the size is no longer specified when an acetabular or femoral neck fracture is associated.
- AO classification (1980)
It describes the infrafoveal fragments without specifying their size (C13) and the possible association with a cervical fracture (C3) (12); it introduces the notion of subchondral

compression (C21). Association with a fracture of the posterior wall of the acetabulum is not included!

- Yoon classification (2011)
It individualises the infrafoveal fragments of a quarter (Type I) and a third of the femoral head (Type II) and the extrafoveal fragments of a half of the head (Type III) (13). Type IV, femoral head size reduction, has not really been observed. Associated fractures of the acetabulum or femoral neck are not included!
- Chiron (2013) classification (Fig. 4)
This classification is based on CT analysis of 75 consecutive cases. It combines the description of femoral head fragments of different sizes (loose bodies, 1/4, 1/3, 1/2) which may be isolated (Group A; 35%) or associated with a fracture of the posterior wall of the acetabulum (Group B; 59%) or with a cervical fracture (Group C; 6%); the notion of small free osteochondral fragments (loose bodies) is introduced (Type I; 31%), that of femoral head compaction reintroduced (Type V; 1%) (1, 7, 14, 15). It enables specification of the choice between treatment by ablation and by screwing of the head fragments and examination of the long-term results. The frequency (59%) of associated posterior wall fractures is noteworthy (Park 44%) (16) (Figs 5 and 6).

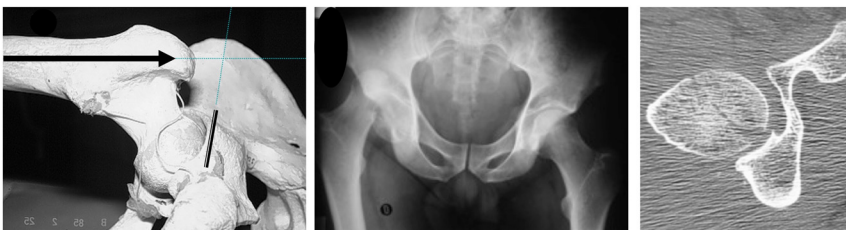

Figure 2
Mechanism of a pure suprafoveal fracture or a fracture associated with the posterior wall of the acetabulum.

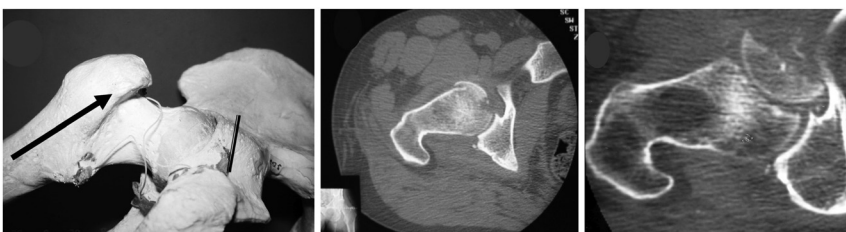
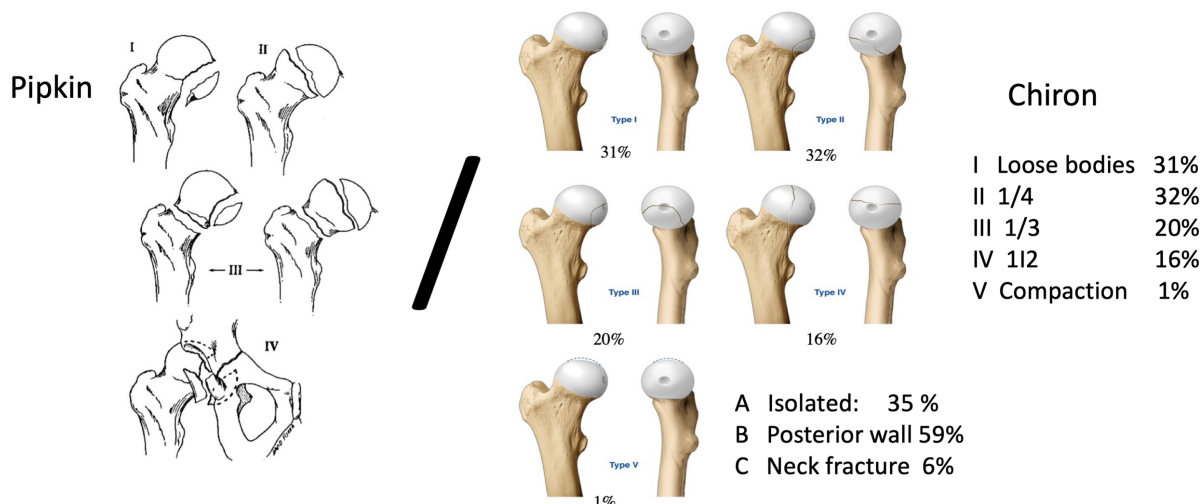


Figure 3
Mechanism of an infrafoveal fracture of 1/4 or 1/3 of the head.



Equivalence	Chiron 1			Chiron 2			Chiron 3			Chiron 4			Chiron 5		
	A	B	C	A	B	C	A	B	C	A	B	C	A	B	C
Pipkin 1	x			x			x								
Pipkin 2										x					
Pipkin3			x			x			x			x			x
Pipkin4		x			x			x			x			x	

Figure 4

Classification of Pipkin 1957 and Chiron 2013.

What to do in an emergency?

In case of a posterior dislocation, the pain is sharp, the classic position is flexion, adduction, internal rotation. Before reduction, EPN-type palsy with loss of toe extension and ankle flexion, isolated or associated with IPN palsy with loss of toe flexion and ankle extension should be verified.

An antero-posterior pelvic X-ray is sufficient in case of emergency to objectivise a hip dislocation with rupture of the cervico obturator line of Shenton: a head fracture (1/4, 1/3, 1/2) is visible on a dislocated hip (Fig. 7).

An emergency reduction of the dislocation is required, preferably within 6 h of the trauma, to limit the risk of femoral head necrosis and damage to the sciatic nerve by ischaemic compression (1, 17). The risks during reduction should be borne in mind: aggravation of chondral lesions, foreign bodies entrapped in the joint space, femoral neck fracture, especially with suprafoveal fracture (Pipkin II, Yoon III, Chiron IV) (18, 19, 20). Under anaesthesia, in the operating room, the classic Boehler manoeuvre or the Allis manoeuvre (18) (in dorsal decubitus on a hard surface, with counter-pressure on the anterior superior iliac crests, traction is performed in the axis of the femur, with the hip and knee in 90° flexion, and the limb adducted and internally rotated) may be used preferentially.

There are several possibilities at this stage:

- The reduction is stable: control radiography confirms adequate reduction; the patient is placed on non-weight-bearing restriction before a delayed CT scan is performed to analyse the size, position and congruence of the post-reduction fragments and the presence or absence of intra-articular foreign bodies (this examination is essential); it makes it possible to adjust the course of delayed action to be taken.
- Reduction is uncontrollable: this occurs most often when there are associated posterior wall fractures (Pipkin III, Chiron B). Temporary traction or an open procedure should be discussed immediately.
- The dislocation is irreducible (21): The reduction technique is wrong! A surgeon in training should not hesitate to call a more experienced surgeon to the rescue! This can also be observed in isolated fractures of the third or half of the femoral head (Pipkin I & II, Chiron A III & IV); the cancellous bone of the femoral head then creates a notch with the posterior wall which can be responsible for a fracture especially in type IV (21). An open reduction by posterior approach must be performed with reduction and osteosynthesis of the fragment as described in the following section (22).
- Iatrogenic femoral neck fracture: A total hip arthroplasty is to be planned as an emergency or delayed measure (23); a few clinical cases of rescue have been described (24, 25).

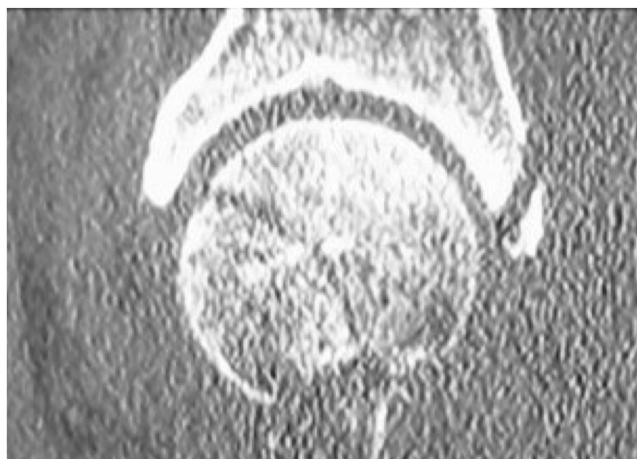


Figure 5
Pipkin III, Chiron 3B good congruence.

Secondary treatment

When a stable reduction has been obtained in an emergency, a decision should be made for further management: orthopaedic treatment, removal of foreign bodies or the loose fragment of the femoral head, osteosynthesis, reduction, total hip replacement. The course of action is based on the evaluation of an early CT scan (1, 26, 27): this examination, which is essential today, reveals entrapped foreign bodies that are not visible on standard X-ray and enables assessment of the congruence of the loose fragment, the size and position.

- Orthopaedic treatment consists of 2 months of non-weight-bearing followed by progressive weight-bearing, based on satisfactory control radiographies;

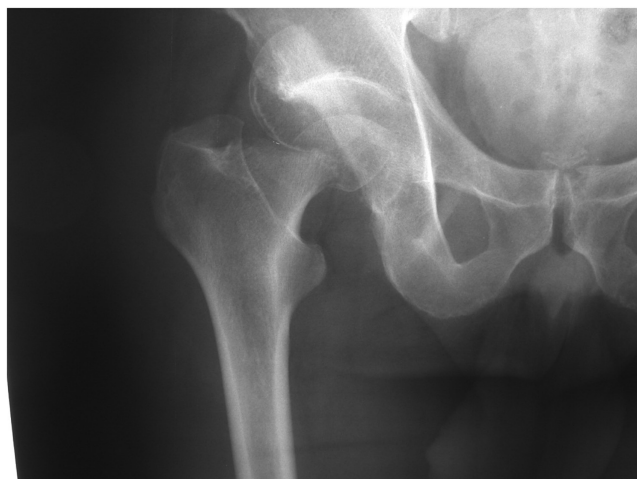

Figure 6
Pipkin II, Chiron 4C: neck fracture.

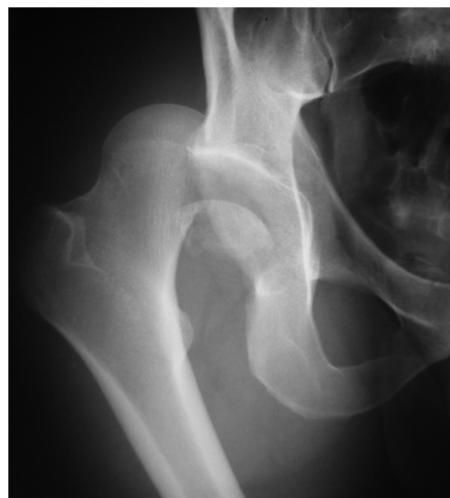

Figure 7
AP view; dislocated head: Pipkin 1, Chiron 3A.

it is intended for cases of reduction with perfect congruence (Fig. 8).

- Removal of foreign bodies is essential before weight-bearing; arthroscopy with decoaptation of the joint space is the ideal way to remove entrapped foreign bodies (28, 29, 30, 31) (Fig. 9); a simple lavage can be effective (32).
- A displaced $\frac{1}{4}$ or $\frac{1}{3}$ fragment after reduction can be resected (1, 7) (Fig. 10) or reduced/screwed (29); nowadays, screw osteosynthesis is done with Erberth-type double-compression pin-guided screws (30, 33, 34, 35, 36) (Fig. 11); it may be wise to use resorbable screws. Arthroscopy is more difficult for ablation or osteosynthesis of $\frac{1}{3}$ or $\frac{1}{4}$ fragments located inferiorly and anteriorly on the head (28, 29, 30, 37). A posterior approach requires relaxation of the hip and provides reduced access to the lower, anterior part of the femoral head (38). An anterolateral or anterior approach provides better access (35, 36,

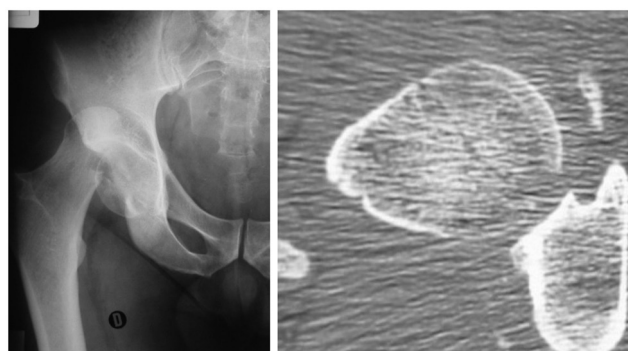


Figure 8
Pipkin 1, Chiron 3A good congruence.

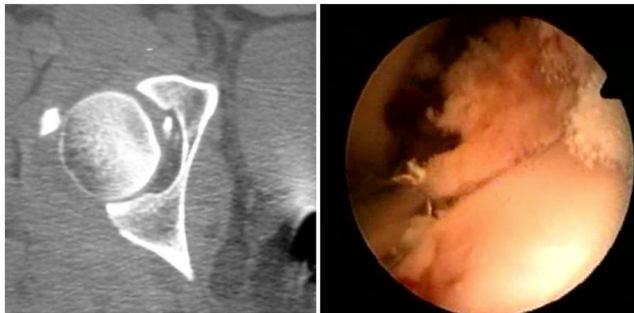


Figure 9
Chiron 1A: loose bodies, arthroscopic resection.

39). Ludloff medial approaches, modified by Ferguson (40, 41), which pass between the adductor longus/brevis and magnus provide sufficient access for ablation or osteosynthesis, but the view is limited, the obturator nerve is in the line of approach. The medial hip approach (33, 42) which passes in front of the adductors is perfectly adapted to this type of procedure; it provides a wide direct view, leaving the obturator nerve protected by the adductor longus muscle (Fig. 12).

- A 1/2 head fragment displaced after reduction can be screwed in; in that case, a posterior approach is more suitable; it is best to avoid a double traumatic posterior and surgical anterior dislocation.
- When there is an associated wall fracture, it must be reduced and stabilised by osteosynthesis. A posterior approach is then required. Osteosynthesis is applicable in some cases with cervical fracture (43).
- A hip prosthesis may be indicated when the subject is elderly, the bone porotic, and there is an associated Garden III or IV cephalic fracture (44).

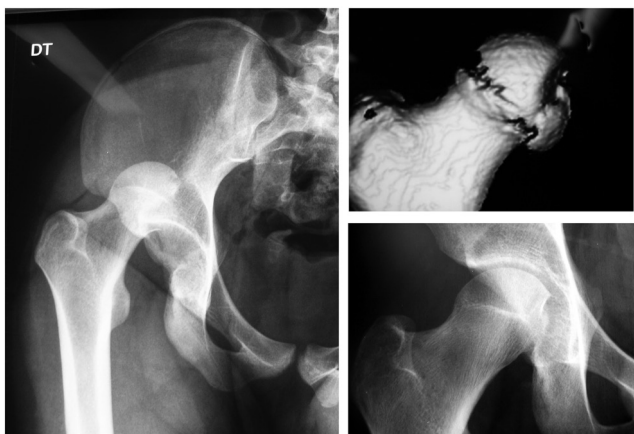

Figure 10
Pipkin I, Chiron 2A: resection of the fragment.

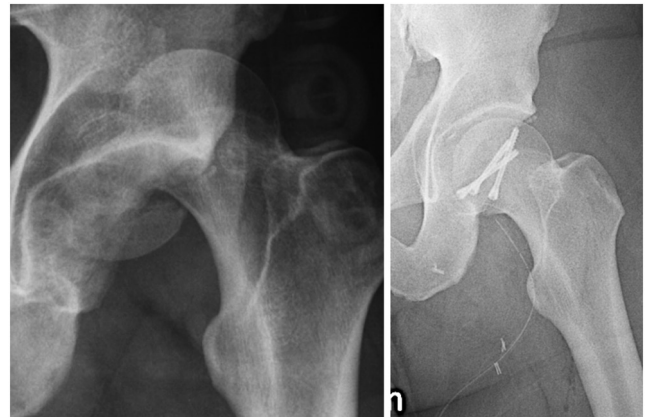


Figure 11
Pipkin I, Chiron 3A: Herbert screwing.

- Sciatic nerve palsy (1, 2): If the external popliteal nerve is affected in isolation (24% of Pipkin 3 and Chiron group B), in most cases, the radicular lesion is a neurapraxia or axonotmesis (45). Spontaneous recovery, which occurs in 82% of the cases, should be allowed. In case of an EPN+IPN lesion, radicular damage with neurotmesis type lesions of the EPN fibres: transfer of the posterior leg muscle tendon if there is no recovery after 1 year.

Delayed treatment

A malunion of the femoral head created by consolidation of a Type 2 or 3 (quarter and third of the femoral head) fragment in a poor position is responsible for groin pain in the region of the adductor muscles and a possible sensation of adhesion. Secondarily, the shape of the

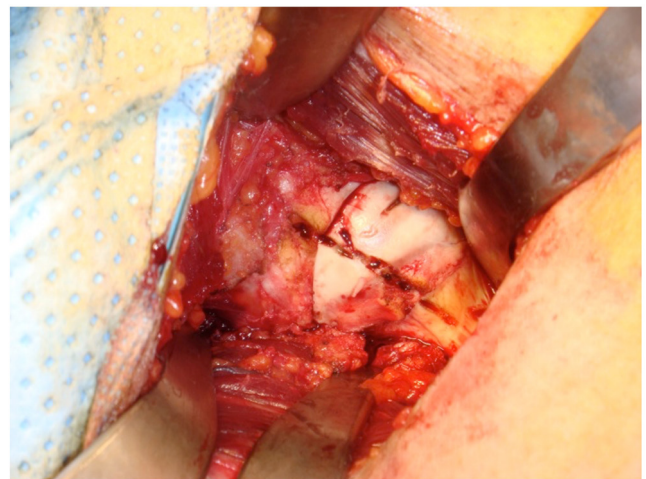


Figure 12
Medial approach view.

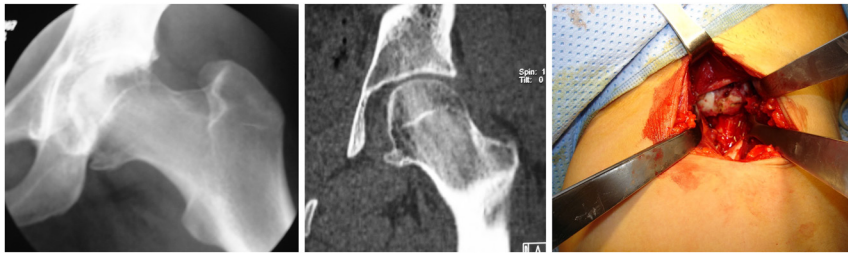

Figure 13
Malunion; late medial approach resection.

femoral head can still be regularised by a medial approach with good functional results (1, 46) (Fig. 13).

Results

The analysis of the results is based on publications after the year 2000 concerning over 10 cases with at least 3 years of follow-up, that is, 195 cases of all types (excluding femoral neck fractures) with a mean follow-up of 34 months (20–45 months) (7, 16, 40, 47) including: 16/195 cases of necrosis (8.2%), 64/195 cases of arthrosis visible on radiography (32%), 44/195 (22.5%) cases of secondary total hip replacement (THR) for arthrosis and necrosis. The incidence of sciatic nerve palsy could be 4% (48).

Only Type III Pipkin, Chiron IV (1 case A, 1 case B, 1 case C) ½ femoral head fractures led to emergency THR (1).

The overall percentage of osteoarthritis is high, but osteoarthritis is relatively well tolerated with an Excellent Epstein score, and good for Park of 71% (16), 74% for

Xiao (49) and 78% for Tonetti (7); a THR percentage of 22.5% for necrosis and arthrosis with many cases of good tolerability of osteoarthritis (1). Cases treated by orthopaedics provide equivalent results to those treated by ablation or osteosynthesis, provided that the reduction is adequate and no foreign bodies are entrapped (50). Foreign body or ¼ head fragment ablation (Chiron I and II) consistently yields good long-term results (7, 40, 42). Group III (1/3) with screws had the longest retrospect with the highest percentage of THR (39–45%), but in the series examined (1, 7, 33), few cases were reduced and screwed, the approaches were not very suitable, the reductions were inadequate. However, it seems that reduction and screwing of this Chiron III type is the best solution, which is increasingly used thanks to the contribution of CT, compression screws and anterior or medial approaches (16, 33, 35, 40, 51). The existence of an associated posterior wall fracture is not a serious factor if the fractures are adequately reduced and osteosynthesised (1, 7, 52).

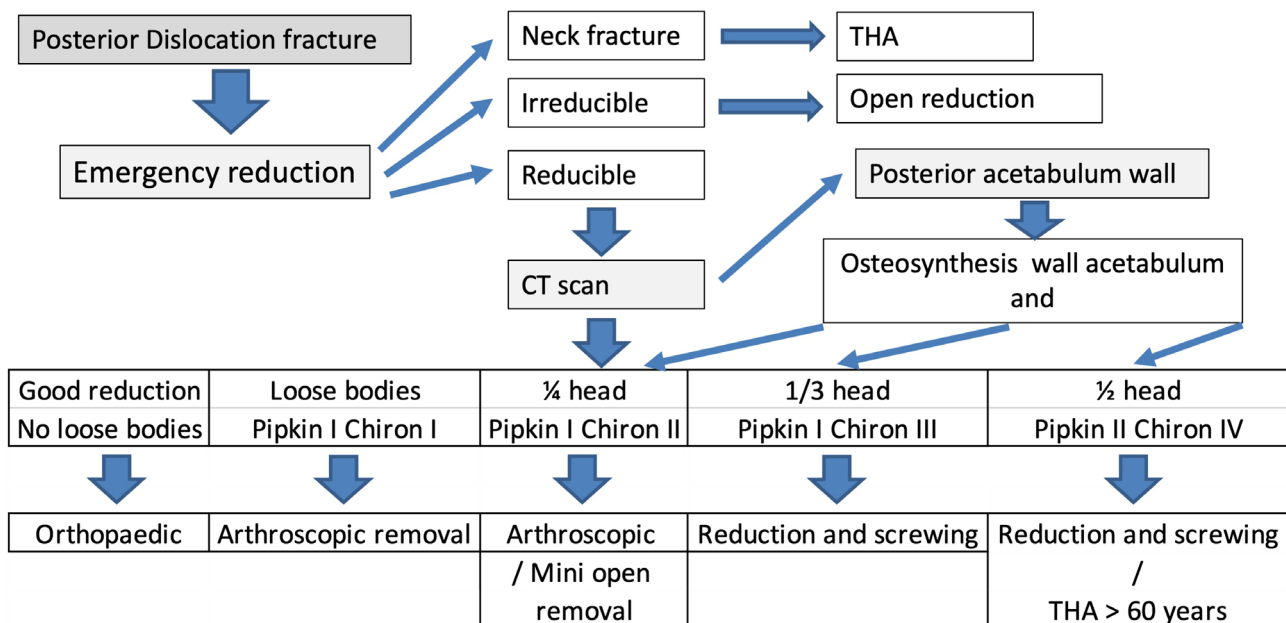


Figure 14
Flowchart: How to deal with.

Summary

The current approach can be summarised as follows (Fig. 14):

- In an emergency, the dislocation must be reduced; if reduction is impossible, a surgery is required. Beware of iatrogenic femoral neck fractures!
- For delayed treatment:
 - A CT scan is essential before treatment.
 - Congruence is satisfactory: orthopaedic treatment
 - Intra-articular small loose bodies: ablation under arthroscopy
 - Displaced ¼ head fragment: ablation (arthroscopic) or medial or antero medial screwing
 - Displaced ⅓ head fragment: medial or antero-medial screwing
 - Displaced ½ head fragment: posterior screwing
 - Fracture of the posterior wall of the acetabulum: posterior osteosynthesis
 - Femoral neck fracture: osteosynthesis or THR
 - EPN palsy: wait for recovery.
 - EPN+IPN palsy: Wait for 1 year and then anterior transfer of the posterior tibial muscle.

ICMJE Conflict of Interest Statement

The authors declare that there is no conflict of interest that could be perceived as prejudicing the impartiality of the research reported.

Funding Statement

This work did not receive any specific grant from any funding agency in the public, commercial, or not-for-profit sector.

References

1. Chiron P, Lafontan V & Reina N. Fracture-dislocations of the femoral head. *Orthopaedics and Traumatology, Surgery and Research* 2013 **99** (1 Supplement) S53–S66. (<https://doi.org/10.1016/j.otsr.2012.11.007>)
2. Decoulx P, Decoulx J, Duquennoy A, Spy E & Lob G. Sciatic paralysis of radicular origin following hip fracture and dislocation. *Revue de Chirurgie Orthopédique et Réparatrice de l'Appareil Moteur* 1971 **57** 355–373.
3. Nolte PC, Franke J, Grutzner PA & Keil H. Reconstruction of a fracture of the posterior acetabular wall with Pipkin fracture and lesion of the sciatic nerve after dorsal hip dislocation. *Der Unfallchirurg* 2020 **123** 413–418. (<https://doi.org/10.1007/s00113-020-00783-w>)
4. Anakwenze OA, Kancherla V, Major NM & Lee GC. Isolated sciatic nerve entrapment by ectopic bone after femoral head fracture-dislocation. *American Journal of Orthopedics* 2013 **42** 275–278.
5. Hardy SL. Femoral nerve palsy associated with an associated posterior wall transverse acetabular fracture. *Journal of Orthopaedic Trauma* 1997 **11** 40–42. (<https://doi.org/10.1097/00005131-199701000-00010>)

6. Liu J, Li Z, Ding J, Huang B & Piao C. Femoral neck fracture combined with anterior dislocation of the femoral head: injury mechanism and proposed novel classification. *BMC Musculoskeletal Disorders* 2021 **22** 810. (<https://doi.org/10.1186/s12891-021-04703-w>)
7. Tonetti J, Ruatti S, Lafontan V, Loubignac F, Chiron P, Sari-Ali H & Bonneville P. Is femoral head fracture-dislocation management improvable: a retrospective study in 110 cases. *Orthopaedics and Traumatology, Surgery and Research* 2010 **96** 623–631. (<https://doi.org/10.1016/j.otsr.2010.03.020>)
8. Durand Y, Bruyere C, Saglini M & Michel-Traverso A. Traumatic obturator hip dislocation with marginal femoral head fracture in a 15-year-old adolescent: a high-energy trauma—a case report and a review of the literature. *Case Reports in Orthopedics* 2018 **2018** 7268032. (<https://doi.org/10.1155/2018/7268032>)
9. Shaikh A, Desai M, Kantanavar R & Shah K. Femoral head fracture without associated hip dislocation. *Arthroplasty Today* 2021 **8** 145–149. (<https://doi.org/10.1016/j.artd.2021.02.007>)
10. Pipkin G. Treatment of grade IV fracture-dislocation of the hip. *Journal of Bone and Joint Surgery: American Volume* 1957 **39** 1027–1042.
11. Romeo NM & Firoozabadi R. Classifications in brief: the Pipkin classification of femoral head fractures. *Clinical Orthopaedics and Related Research* 2018 **476** 1114–1119. (<https://doi.org/10.1007/s11999-0000000000000045>)
12. Muller ME. Classification and international AO-documentation of femur fractures. *Unfallheilkunde* 1980 **83** 251–259.
13. Yoon PW, Jeong HS, Yoo JJ, Koo KH, Yoon KS & Kim HJ. Femoral head fracture without dislocation by low-energy trauma in a young adult. *Clinics in Orthopedic Surgery* 2011 **3** 336–341. (<https://doi.org/10.4055/cios.2011.3.4.336>)
14. Xu M, Motomura G, Utsunomiya T, Ikemura S, Yamaguchi R, Hatanaka H, Baba S, Kawano K & Nakashima Y. Traumatic subchondral fracture of the femoral head occurring concurrently with contralateral acetabular fracture. *Journal of Orthopaedic Science* 2022 **27** 495–499. (<https://doi.org/10.1016/j.jos.2019.05.016>)
15. Poletti PA, Sahin M, Peter R, Boudabbous S, Herpe G, Rutschmann OT & Platon A. Femoral head subchondral impaction on CT: what does it mean in patients with acetabular fracture? *Skeletal Radiology* 2019 **48** 939–948. (<https://doi.org/10.1007/s00256-018-3100-8>)
16. Park KS, Lee KB, Na BR & Yoon TR. Clinical and radiographic outcomes of femoral head fractures: excision vs. fixation of fragment in Pipkin type I: what is the optimal choice for femoral head fracture? *Journal of Orthopaedic Science* 2015 **20** 702–707. (<https://doi.org/10.1007/s00776-015-0732-6>)
17. Wang S, Li B, Zhang Z, Yu X, Li Q & Liu L. Early versus delayed hip reduction in the surgical treatment of femoral head fracture combined with posterior hip dislocation: a comparative study. *BMC Musculoskeletal Disorders* 2021 **22** 1057. (<https://doi.org/10.1186/s12891-021-04968-1>)
18. Ma L, Wu H, Hou Z, Li Z & Li H. Value of modified Allis technique in closed reduction of posteriorly dislocated hip with Pipkin I/II fracture. *Zhonghua Yi Xue Za Zhi* 2014 **94** 533–535.
19. Paredes-Vazquez R, Avitia-Enrique DE, Castellanos-Alfaro A & Chavajay-Cox CG. Iatrogenic femoral head fracture during a closed reduction of posterior dislocation of hip. Case report. *Acta Ortopédica mexicana* 2018 **32** 234–239.
20. Park KH, Kim JW, Oh CW, Kim JW, Oh JK & Kyung HS. A treatment strategy to avoid iatrogenic Pipkin type III femoral head fracture-dislocations. *Archives of Orthopaedic and Trauma Surgery* 2016 **136** 1107–1113. (<https://doi.org/10.1007/s00402-016-2481-1>)

- 21. Mehta S & Routt Jr ML.** Irreducible fracture–dislocations of the femoral head without posterior wall acetabular fractures. *Journal of Orthopaedic Trauma* 2008 **22** 686–692. (<https://doi.org/10.1097/BOT.0b013e31818e2a86>)
- 22. Tang Y, Liu Y, Zhu Y, Li J, Li W, Li Q & Jia Y.** Surgical hip dislocation approach for treatment of femoral head fracture. *Zhongguo Xiu Fu Chong Jian Wai Ke Za Zhi* 2015 **29** 1327–1331.
- 23. Thorat B, Singh A, Arshad M, Salokhe S & Mavani R.** Acute primary total hip arthroplasty for combined posterior acetabulum fracture with ipsilateral associated posteriorly dislocated femoral head with femoral neck fracture. Using of femoral head as an autograft would be an advantage. *Journal of Orthopaedic Case Reports* 2021 **11** 85–90. (<https://doi.org/10.13107/jocr.2021.v11.i04.2164>)
- 24. Li QW, Zhou CS & Li YP.** Case report of a delayed iatrogenic Pipkin type III femoral head fracture–dislocation. *Medicine* 2022 **101** e28773. (<https://doi.org/10.1097/MD.00000000000028773>)
- 25. Wang SX, Li BH, Li J, Huang FG, Xiang Z, Zhong G, Fang Y, Yi M, Zhao XD & Liu L.** Middle-term follow-up results of Pipkin type IV femoral head fracture patients treated by reconstruction plate and bioabsorbable screws. *Chinese Journal of Traumatology* 2018 **21** 170–175. (<https://doi.org/10.1016/j.cjtee.2017.12.004>)
- 26. Richardson P, Young JW & Porter D.** CT detection of cortical fracture of the femoral head associated with posterior hip dislocation. *American Journal of Roentgenology* 1990 **155** 93–94. (<https://doi.org/10.2214/ajr.155.1.2112874>)
- 27. Calisir C, Fishman EK, Carrino JA & Fayad LM.** Fracture–dislocation of the hip: what does volumetric computed tomography add to detection, characterization, and planning treatment? *Journal of Computer Assisted Tomography* 2010 **34** 615–620. (<https://doi.org/10.1097/RCT.0b013e3181d344fb>)
- 28. Aprato A, Buzzone M, Di Benedetto P & Masse A.** Surgical hip dislocation vs arthroscopy for fixation of subfoveal femoral head fractures: a new technique for Pipkin type I fractures. *Acta Bio-Medica* 2021 **92** (Supplement 3) e2021016. (<https://doi.org/10.23750/abm.v92iS3.11724>)
- 29. Hsu SL, Chen CY, Ko JY, Hsu CH, Liu HC & Lu YD.** Hip arthroscopy–assisted reduction and fixation for femoral head fracture dislocations: clinical and radiographic short-term results of seven cases. *Journal of Orthopaedic Surgery* 2019 **27** 2309499019881865. (<https://doi.org/10.1177/2309499019881865>)
- 30. Park MS, Her IS, Cho HM & Chung YY.** Internal fixation of femoral head fractures (Pipkin I) using hip arthroscopy. *Knee Surgery, Sports Traumatology, Arthroscopy* 2014 **22** 898–901. (<https://doi.org/10.1007/s00167-013-2821-4>)
- 31. Chernchujit B, Sanguanjit P, Arunakul M, Jitapankul C & Waitayawinyu T.** Arthroscopic loose body removal after hip fracture dislocation: experiences in 7 cases. *Journal of the Medical Association of Thailand* 2009 **92** (Supplement 6) S161–S164.
- 32. Marecek GS & Routt Jr ML.** Percutaneous manipulation of intra-articular debris after fracture–dislocation of the femoral head or acetabulum. *Orthopedics* 2014 **37** 603–606. (<https://doi.org/10.3928/01477447-20140825-04>)
- 33. Cavaignac E, Laumond G, Regis P, Murgier J, Reina N & Chiron P.** Fixation of a fractured femoral head through a medial hip approach: an original approach to the femoral head. *Hip International* 2015 **25** 488–491. (<https://doi.org/10.5301/hipint.5000248>)
- 34. Hu LY, Jia QY, Yu Y, Cao Y & Zheng SQ.** Clinical effects of internal fixation with Herbert screws for the treatment of Pipkin femoral head fractures. *Zhongguo Gu Shang* 2016 **29** 162–166.
- 35. Sun Z, Jiang L, Chen R, Zhao L & Li X.** Clinical effects of direct anterior internal fixation with Herbert screws on hip joint function and quality of life in patients with Pipkin II femoral head fractures. *Archives of Orthopaedic and Trauma Surgery* 2021. (<https://doi.org/10.1007/s00402-021-03973-2>)
- 36. Wang ZH, Li KN, Zhao P, Chen ED & Zheng J.** In situ reduction and fixation of the anterior medial fenestration approach for femoral head fracture. *Orthopaedic Surgery* 2019 **11** 1163–1172. (<https://doi.org/10.1111/os.12578>)
- 37. Lansford T & Munns SW.** Arthroscopic treatment of Pipkin type I femoral head fractures: a report of 2 cases. *Journal of Orthopaedic Trauma* 2012 **26** e94–e96. (<https://doi.org/10.1097/BOT.0b013e3182323f4f>)
- 38. Wang CG, Li YM, Zhang HF, Li H & Li ZJ.** Anterior approach versus posterior approach for Pipkin I and II femoral head fractures: a systemic review and meta-analysis. *International Journal of Surgery* 2016 **27** 176–181. (<https://doi.org/10.1016/j.ijss.2016.02.003>)
- 39. Wang ZH, Li KN, Lan H, Chen ED & Zheng J.** Anatomical study and clinical application of in situ reduction and fixation of anterior medial fenestration approach of femoral head fracture. *Zhonghua Wai Ke Za Zhi* 2021 **59** 752–759. (<https://doi.org/10.3760/cma.j.cn112139-20210426-00187>)
- 40. Abdelazeem A, Fahmy M & Abdelazeem H.** Modified Ludloff’s medial approach for management of Pipkin’s type I femoral head fracture. *International Orthopaedics* 2021 **45** 1591–1598. (<https://doi.org/10.1007/s00264-020-04667-x>)
- 41. Ferguson Jr AB.** Primary open reduction of congenital dislocation of the hip using a median adductor approach. *Journal of Bone and Joint Surgery: American Volume* 1973 **55** 671–689. (<https://doi.org/10.2106/00004623-197355040-00001>)
- 42. Chiron P, Murgier J, Cavaignac E, Pailhe R & Reina N.** Minimally invasive medial hip approach. *Orthopaedics and Traumatology, Surgery and Research* 2014 **100** 687–689. (<https://doi.org/10.1016/j.otsr.2014.06.009>)
- 43. Tannast M, Mack PW, Klaeser B & Siebenrock KA.** Hip dislocation and femoral neck fracture: decision-making for head preservation. *Injury* 2009 **40** 1118–1124. (<https://doi.org/10.1016/j.injury.2009.06.166>)
- 44. Tosounidis T, Aderinto J & Giannoudis PV.** Pipkin type-III fractures of the femoral head: fix it or replace it? *Injury* 2017 **48** 2375–2378. (<https://doi.org/10.1016/j.injury.2017.10.002>)
- 45. Seddon HJ.** A classification of nerve injuries. *BMJ* 1942 **2** 237–239. (<https://doi.org/10.1136/bmj.2.4260.237>)
- 46. Cole HW, Rooks A, Blackstone R, Franco J, Huff N & Gehlert R.** Arthroscopic decompression of a malunited infrafoveal femoral head fracture: a case report. *JBJS Case Connector* 2020 **10** e1900528. (<https://doi.org/10.2106/JBJS.CC.19.00528>)
- 47. Mostafa MF, El-Adl W & El-Sayed MA.** Operative treatment of displaced Pipkin type I and II femoral head fractures. *Archives of Orthopaedic and Trauma Surgery* 2014 **134** 637–644. (<https://doi.org/10.1007/s00402-014-1960-5>)
- 48. Giannoudis PV, Kontakis G, Christoforakis Z, Akula M, Tosounidis T & Koutras C.** Management, complications and clinical results of femoral head fractures. *Injury* 2009 **40** 1245–1251. (<https://doi.org/10.1016/j.injury.2009.10.024>)
- 49. Xiao B, Cao Z & He A.** Clinical efficacy of surgical treatment for Pipkin fracture in 17 cases. *Zhong Nan Da Xue Xue Bao Yi Xue Ban* 2019 **44** 1391–1396. (<https://doi.org/10.11817/j.issn.1672-7347.2019.180674>)
- 50. Chen ZW, Lin B, Zhai WL, Guo ZM, Liang Z, Zheng JP, Lian KJ & Ding ZQ.** Conservative versus surgical management of Pipkin type I fractures associated with posterior dislocation of the hip: a randomised controlled trial. *International Orthopaedics* 2011 **35** 1077–1081. (<https://doi.org/10.1007/s00264-010-1087-4>)

51. Bettinelli G, Placella G, Moharamzadeh D, Belluati A & Salini V. Articular femoral head fracture management: a meta-analysis of literature. *Indian Journal of Orthopaedics* 2021 **55** (Supplement 2) 304–313. (<https://doi.org/10.1007/s43465-021-00431-4>)

52. Chen ZW, Zhai WL, Ding ZQ, Lian KJ, Kang LQ, Guo LX, Liu H & Lin B. Operative versus nonoperative management of Pipkin type-II fractures associated with posterior hip dislocation. *Orthopedics* 2011 **34** 350. (<https://doi.org/10.3928/01477447-20110317-09>)