Do the Functional Results of Surgical Treatment of Patients with Neglected Developmentally Dislocated Hips Remain the Same with Longer Follow-Up?

Pablo Castañeda, MD, Erika Arana, MD, Cristina Carbajal, MD, Felipe Haces, MD, and Nelson Cassis, MD

Abstract

Background: The results of treatment for neglected developmental dysplasia of the hips (DDH) in children remains controversial. We sought to determine the clinical and radiographic result of patients with neglected DDH with special emphasis on the functional outcome as determined by the Pediatric Outcomes Data Collection Instrument (PODCI) and determine which preoperative variables were related to the result. We also sought to determine if the functional results remain the same over time and if there is there a preoperative variable that can predict a poor outcome.

Methods: This was a retrospective review of 15 patients (19 hips, 11 unilateral and 4 bilateral) treated after the age of 6 years (mean: 7.6 years) with one stage open reduction, femoral shortening, and innominate osteotomy with a minimum follow-up of 15 years. Clinical and radiographic evaluations were performed at 10 years and 15 years after the index procedure. Functional outcome was determined using the PODCI scale and the Iowa Hip Score; the radiographic result was evaluated with the Severin classification, the center-edge angle, and the Tönnis grade of osteoarthritis. Linear regression analysis was used to determine the influence of preoperative variables on the result.

Results: The patients were evaluated at two points in time: the first evaluation was performed at a mean 10.7 years after surgery (range: 10.0 to 12.2 years); at that time, the patients mean age was 17.8 years; 11 had pain and 14 had a limp, the mean Iowa hip score was 73.5 and the mean PODCI score was 88.05. The mean CE angle was 26.9°, one hip was considered a Severin type I, six as type II, eight as type III, and four as type IV; eight hips were considered Tönnis grade I, seven grade II, and four grade III. The second evaluation was performed at a mean 15.8 years after surgery (range: 15.1 to 17.3 years); at that time, the patients mean age was 22.9 years; 14 had pain and 14 had a limp, the mean Iowa hip score was 67.8, and the mean PODCI score was 85.73. The mean CE angle was 29.7°, one hip was considered a Severin type I, four as type II, 10 as type III, and four as type IV; two hips were considered Tönnis grade I, five grade II, nine grade III, and three grade IV. The results were significantly worse than those seen at the first evaluation. Linear regression analysis showed a tendency toward worse functional and radiographic results with increasing age at the time of treatment as well as with time of follow-up.

Conclusions: The results demonstrate a directly inverse relationship between age at the time of treatment and functional and radiographic results for patients with neglected DDH. A progressive deterioration of the results with further follow-up was also found.

Despite increased awareness and early screening programs, there are still many patients with developmental dysplasia of the hip (DDH) who are not diagnosed until after walking age and it is not uncommon to see older children who have received no treatment, especially in developing countries. The long-term follow-up and results of surgical treatment for younger children have been discussed by many authors and are generally considered to be good[1-5]; however, for older children it is still not yet clear whether treatment produces a worse result than does no treatment, and there is no consensus regarding the ideal management of an older child with a dislocated hip.

Any kind of medical treatment should have the purpose of producing a better outcome when compared to the natural

Pablo Castañeda, MD, Erika Arana, MD, Cristina Carbajal, MD, Felipe Haces, MD, and Nelson Cassis, MD, Shriners Hospital for Children, Mexico City, Mexico.
Correspondence: Pablo Castañeda, MD, Department of Orthopedic Surgery, NYU Langone Orthopedic Hospital, NYU Langone Health, 301 East 17th Street, New York, New York 10003, USA; pablo.castaneda@nyulangone.org.

Castañeda P, Arana E, Carbajal C, Haces F, Cassis N. Do the functional results of surgical treatment of patients with neglected developmentally dislocated hips remain the same with longer follow-up? Bull Hosp Jt Dis. 2021;79(2):124-9.

history of the condition being treated. The management of dislocated hips in older children has been fraught with complications including failure to achieve reduction, a high rate of avascular necrosis (AVN),[6,7] joint stiffness, femoral head deformity, persistent subluxation, and redislocation. Avascular necrosis does not usually occur in untreated patients and, in a natural history study of untreated patients by Crawford et al.,[8] it was found that patients had very satisfactory clinical and functional results into middle or even old age.

Another study by Vallamshetla et al.[9] concluded that one-stage correction of congenital dislocation of the hip in an older child is a safe and effective treatment with good results in the short to medium term; however, the mean age at the time of operation was 5 years and 9 months and the issue of determining an upper age limit for the safe reduction of a dislocated hip is still debated.

The goal of surgical treatment is to achieve balance between maintaining a stable concentric reduction with painless range of motion and function in order to obtain a durable hip into adulthood.[10-12] The principal problems encountered when treating these hips are a high riding femoral head, contracted soft tissues, and a severely dysplastic acetabulum.[13] In the older child, these contractures of muscles, tendons, and capsule not only prevent reduction but can result in increased pressure on the developing femoral head during or after reduction leading to ischemia. Traction has been utilized as a means of decreasing the prevalence of ischemia,[13] but there is insufficient evidence to support the consistent use of this treatment.[10] Femoral shortening has been proven to facilitate reduction and does not appear to increase the prevalence of AVN of the femoral head.[10,11] In fact, some consider this to be a protective measure against AVN. It should be noted that the term "avascular necrosis" has recently been replaced by the more accurate term "proximal femoral growth disturbance" as it better reflects the underlying pathophysiology.

The purpose of this study was to determine the clinical and radiographic result of patients with neglected DDH who were treated after the age of 6 years with special emphasis on the functional outcome as determined by the PODCI scale. An attempt was also made to determine which preoperative variables were related to the result.

Materials and Methods

A retrospective review was performed of the charts of 2,217 patients treated at our institution between 1980 and 1995 for DDH; only children over the age of 5.5 years without any previous treatment and a minimum follow-up of 5 years were considered for the study. Patients with a diagnosis of cerebral palsy, spina bifida, and other associated syndromes were excluded. All patients were treated with a single stage open reduction, femoral shortening, and innominate osteotomy.

A total of 15 patients (19 hips; 11 unilateral and 4 bilateral) met the criteria and are included in the study; all patients were girls. The mean age at the time of surgical treatment was 7.6 years old (range: 5.8 to 11.3 years). The preoperatively clinical variables evaluated were the presence of pain and the range of motion; the radiographic variables included the Tönnis classification to evaluate the level of the dislocation[14] and the acetabular index to assess the grade of dysplasia.

Skeletal maturity was assessed with a modification of the Oxford Bone Score,[15] which considers nine distinct areas: the head of the femur, the greater trochanter, the lesser trochanter, the ilium, the ischium, the lip of the acetabulum, the junction of the ischial and pubic rami, the pubis, and the triradiate cartilage. These were all evaluated on anteroposterior radiographs of the pelvis and both hips were graded according to established standards; a point-value was then assigned for each area. The total score was a sum of the score for each distinct area.

Functional outcome was determined using the Pediatric Outcomes Data Collection Instrument (PODCI) and the Iowa Hip Score. The PODCI was developed by the Pediatric Orthopedic Society of North America to measure real-life functional levels of pediatric orthopedic patients; it yields four functional assessment scores, a global function score and a happiness score (each having a possible range from 0 to 100). The adolescent version of the questionnaire was used, which has been previously validated in a similar population of healthy adolescents who obtained scores close to the maximum of 100.[16]

The radiographic result was evaluated with the modified Severin classification, the center-edge (CE) angle, and Sharp's acetabular angle.

The modified Severin system was used to classify results.[17] Type I was assigned if the hip was normal with a CE angle of Wiberg greater than 20°. Type II had a mild deformity of the head or neck but the hip was concentrically reduced and the CE angle was greater than 20°. Type III hips were dysplastic without subluxation and had a CE angle less than 20°. Type IV hips were subluxated with a CE angle of 0° or less. Type V hips had the femoral head articulating within a secondary acetabulum. Type VI hips corresponded to a redislocation.

The Tönnis grade of degenerative joint disease was used to evaluate the degree of osteoarthritis.[18]

Statistical analysis was performed to determine the relationship of preoperative variables to the outcome variables. Paired univariate analysis of the outcome variables was carried out to reduce the set of measured variables for later multivariate analysis, which was done by linear regression, logistic regression, and hazard power ratios. Multivariate analysis was performed with IBM SPSS Statistics software version 16 (IBM, Armonk, New York, USA).

All the clinical and radiographic evaluations were performed at two distinct points in time; the first evaluation was performed at a mean 10.7 years after surgery (range: 10.0 to 12.2 years) and the second evaluation was

performed at a mean 15.8 years after surgery (range: 15.1 to 17.3 years).

Results

Of the 15 patients included, all were girls, 11 had unilateral dislocations and four had bilateral dislocations. None reported pain preoperatively. Preoperative range of motion showed an average flexion of 118° and average preoperative abduction of 39°. Seventeen hips were classified as Tönnis IV and two were classified as Tönnis III. The mean acetabular index was 43° (range: 30° to 56°). The mean Oxford Bone Score was 18.89 (range: 17 to 21).

Two patients presented a redislocation and were treated with revision open reductions, one of them also had a revision innominate osteotomy and one had a varus producing osteotomy of the femur. One patient presented a subtrochanteric fracture of the femur and was treated with closed reduction and spica cast.

The mean follow-up at the first evaluation was at 10.7 years after surgery (range: 10.0 to 12.2 years); at that time,

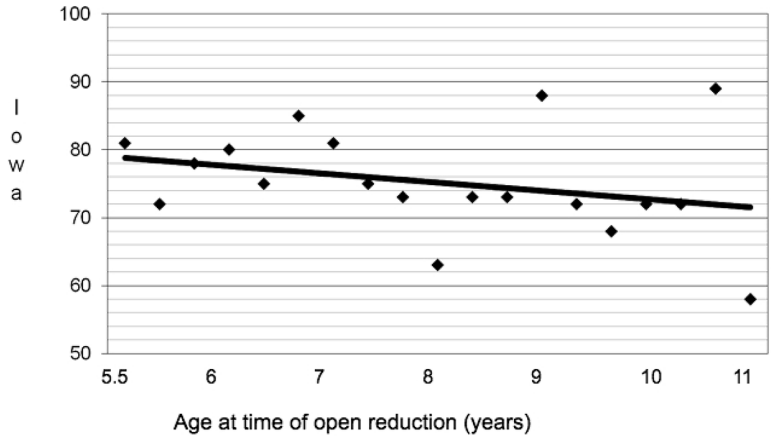

Figure 1 Linear regression analysis of Iowa Hip Score versus age at time of surgery.

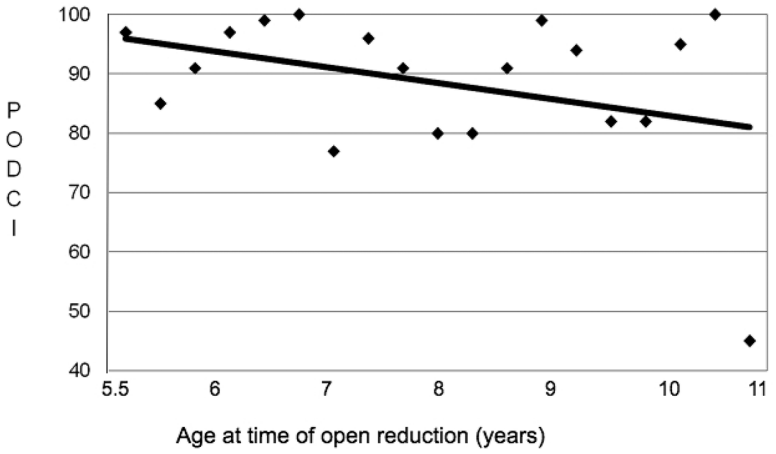

Figure 2 Linear regression analysis of PODCI versus age at time of surgery.

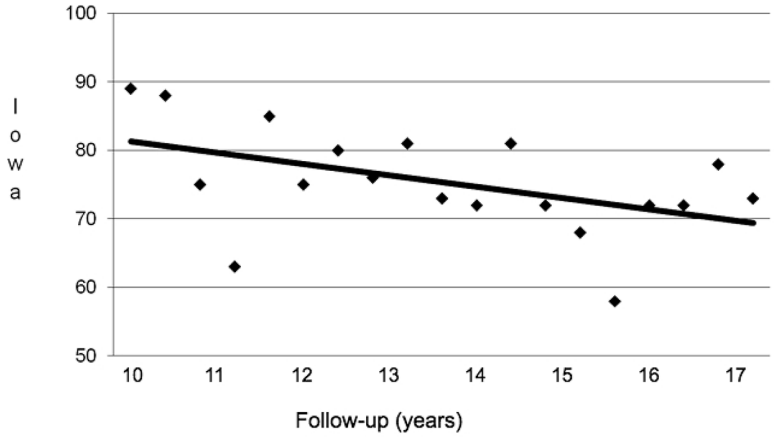

Figure 3 Linear regression analysis of Iowa Hip Score versus follow-up time.

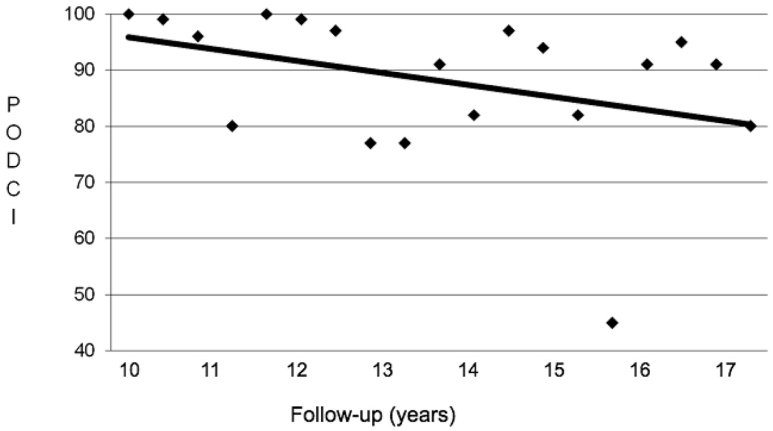

Figure 4 Linear regression analysis of PODCI versus follow-up time.

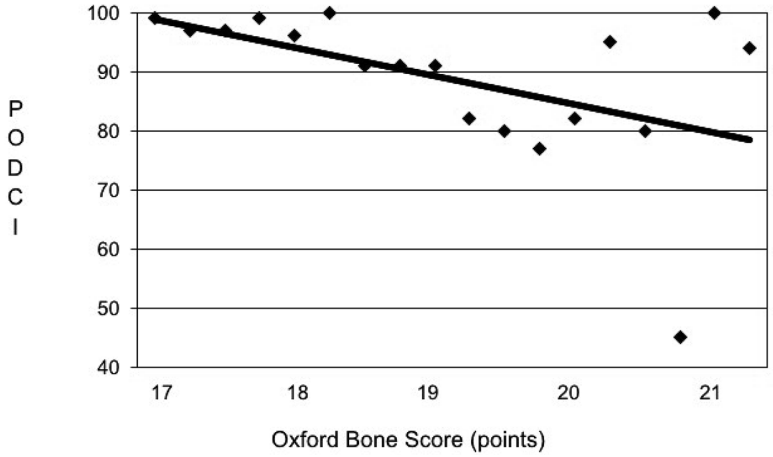

Figure 5 Linear regression analysis of PODCI versus Oxford Bone Score at time of surgery.

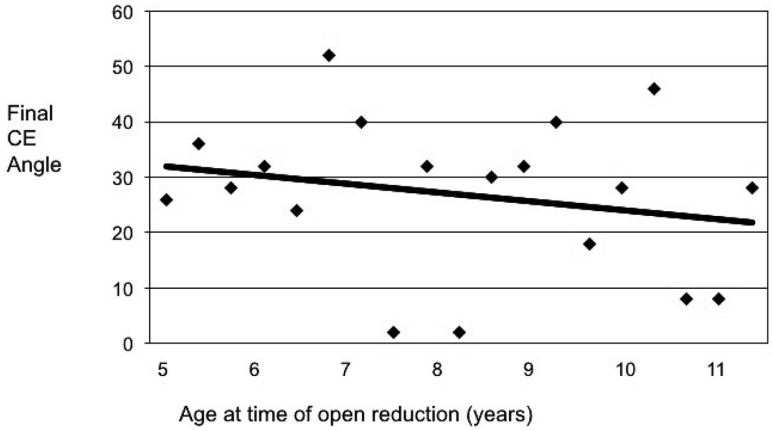

Figure 6 Linear regression analysis of final CE angle versus age at time of surgery.

the patients' mean age was 17.8 years. Eleven had pain, according to the Visual Analog Scale (VAS) for pain the patients reported a mean of 2 (range: 0 to 6); however, if only the patients with pain were included, the mean VAS pain score was 4.6 (range: 2 to 6). Nine patients reported participating in sports at least once a week. Fourteen patients had a limp. The mean Iowa hip score was 73.5 and the mean PODCI score was 88.05. The mean CE angle was 26.9°; one hip was considered a Severin type I, six as type II, eight as type III, and four as type IV. Eight hips were considered Tönnis grade I, seven grade II, and four grade III.

The second evaluation was performed at a mean 15.8 years after surgery (range: 15.1 to 17.3 years). At that time, the patients mean age was 22.9 years. Fourteen had pain and 14 had a limp, the mean Iowa hip score was 67.8 and the mean PODCI score was 85.73. The mean CE angle was 29.7°; one hip was considered a Severin type I, four as type II, 10 as type III, and four as type IV. Two hips were

Table 1 Mean Clinical and Radiographic Outcomes at Initial Follow-Up (10.7 Years) and Final Follow-Up (15.8 Years)

	Initial Follow-Up (10.7 Years)	Final Follow-up (15.8 Years)
Iowa Hip Score	73.6	67.8
PODCI	88.05	85.73
Severin Score	2.7	2.8
Tönnis Grade of OA	1.7	2.6

PODCI, Pediatric Outcomes Data Collection Instrument.

considered Tönnis grade I, five grade II, nine grade III, and three grade IV. Linear regression analysis showed a tendency toward worse functional and radiographic results with increasing age at the time of treatment as well as with time of follow-up, although this was not deemed statistically significant due to the small number of patients.

A definite trend toward a worsening score on both functional scales was seen with increasing age at the time of the open reduction as well as with further follow-up when linear regression analysis was applied (Fig 1 through 4).

The Oxford Bone Score was calculated for all patients at the time of surgery, and the mean score obtained was 18.89 (range: 17 to 21). When linear and logistic regression analysis were applied, the same tendency was observed for both the Iowa Hip Score and the PODCI (Fig. 5). Decreasing outcome measures were found with increasing bone age. Linear and logistic regression analysis showed a tendency toward worse radiographic results with increasing age at the time of treatment.

At the time of the first evaluation (mean: 10.7 years after surgery), all patients were directed to perform physical therapy to strengthen the hip, and the importance of maintaining a body weight was emphasized. Interestingly, no patient showed any improvement on any clinical parameter despite these instructions, and in fact every patient showed worse outcomes at the time of the second evaluation both on the clinical scales and radiographic evaluations employed (Table 1).

The radiographic results showed a similar trend; linear regression analysis for the center-edge angle in relation to the age at the time of surgery showed a similar tendency as the clinical results with the highest CE angles being found in the youngest patients and the lowest being found in the older patients (Fig. 6).

Although our numbers are not large due to the relative paucity of this condition in modern times, we did not find that the one patient who was under six years of age at the time of surgery did significantly better on clinical and radiographic outcome compared to the oldest ones as demonstrated by an Iowa hip score of 82 at the time of first revision for the youngest patient and scores of 92 and 58 for the patients who were 11 years of age at the time of reduction. This large variability in the results makes generalization difficult and we found that the overall results were similar for all age groups.

Discussion

The primary goal of treatment of a developmentally dislocated hip in an older child is to provide painless function of the hip into adulthood. It is not a prerequisite to have a located hip for adequate function to be present as has been stated previously[19,20]; patients with dislocated hips can live normal pain free lives even if it is a unilateral dislocation.

Crawford and Slovek[21] reported on the long-term follow-up of a series of eight patients with untreated dislocated hips of which two were unilateral and found that these patients achieved a better quality of life than have many patients of a similar age who have undergone surgical treatments aimed at reducing such late-presenting hip dislocations.

Although it is still unknown whether there is a specific age when treatment produces a worse result than does no treatment, there have been numerous studies addressing this issue. Salter and Dubos[22] performed one-stage open reduction and innominate osteotomy in children 4 to 10 years of age and noted that 43% remained subluxated or dislocated (Severin class III or IV) at a follow-up of 7 years. Karakas et al.[23] published the results of a similar one-stage procedure after a period of skin traction in children who were at least 4 years old and reported a good or excellent clinical result at an average of 8 years' follow-up. They documented avascular necrosis in only 7% of their patients but did not classify the extent of the necrosis or its relationship to the end results. Klisic and Jankovic[12] also reported on a series of 47 patients undergoing treatment, 68% of whom achieved good or excellent radiographic results; however, they noted that the clinical results were not always in accordance with the radiographic results.

We do not use or advocate preoperative traction, it has been shown that femoral shortening allows the muscles that cross the osteotomy to function as if they were lengthened, it also avoids prolonged hospitalization, and it allows an open reduction to be done at the same time.[11]

Our results show a directly inverse relationship between age at the time of treatment and functional and radiographic results for patients with untreated DDH. Although some authors have reported mid-term radiographic outcomes in older children, it has been considered that the development of complications preclude the reduction of hips in older children, especially if the dislocation is bilateral.

It is difficult to determine a precise age to consider a limit for reduction. However, we could demonstrate that good results are more difficult to obtain with advancing age. This should be considered when deciding whether to perform an open reduction, especially in bilaterally dislocated hips as one must obtain excellent results twice in the same patient to have a better result than would have been obtained without treatment.

We also found a progressive deterioration of the results with further follow-up. Our findings suggest that, although outcomes are satisfactory in the short term, a longer duration of follow-up would show a deterioration of the results. It has been shown previously that even patients with a good Severin grade are predisposed to early osteoarthritis.[12]

There is a case to be made for reducing hips to facilitate a subsequent total hip replacement in adulthood where the placement of the acetabular and femoral components is very difficult in high riding hips.[23] However, this argument is countered by the consideration of the durability of the hip and there is insufficient evidence to support the view that a dislocated hip produces pain earlier in life than a reduced one.[12,24-26] In fact, there is evidence that reducing a dislocated hip in an older child with the subsequent complications, femoral head deformities, and joint stiffness produce a painful hip earlier in life than would no treatment at all.[19,24-26]

Fortunately, with increased awareness and early detection, there are a decreasing number of patients who remain undiagnosed later into life. However, this also means that orthopedic surgeons will be less familiar with the outcomes for these patients and studies like this one should help when faced with a patient of these characteristics.

Disclosure Statement

None of the authors have a financial or proprietary interest in the subject matter or materials discussed herein, including, but not limited to, employment, consultancies, stock ownership, honoraria, and paid expert testimony.

References

1. Ashley RK, Larsen LJ, James PM. Reduction of dislocation of the hip in older children. A preliminary report. J. Bone Joint Surg Am. 1972;54(3):545-50.
2. Berkeley ME, Dickson JH, Cain TE, Donovan MM. Surgical therapy for congenital dislocation of the hip in patients who are twelve to thirty-six months old. J Bone Joint Surg Am. 1984;66(3):412-20.
3. Coleman SS. *Congenital Dysplasia and Dislocation of the Hip*. St. Louis: C.V. Mosby, 1978, pp. 95-154.
4. Galpin RD, Roach JW, Wenger DR, et al. One-stage treatment of congenital dislocation of the hip in older children, including femoral shortening. J Bone Joint Surg Am. 1989;71(5):734-41.
5. The classic. Innominate osteotomy in the treatment of congenital dislocation and subluxation of the hip by Robert B. Salter, J Bone Joint Surg. (Brit) 43B:3:518. 1961. Clin Orthop Relat Res. 1978;(137):2-14.
6. Gage JR, Winter RB. Avascular necrosis of the capital femoral epiphysis as a complication of closed reduction of congenital dislocation of the hip. A critical review of twenty years' experience at Gillette Children's Hospital. J Bone Joint Surg Am. 1972;54(2):373-88.
7. Kalamchi A, MacEwen GD. Avascular necrosis following treatment of congenital dislocation of the hip. J Bone Joint Surg Am. 1980;62(6):876-88.
8. Crawford AH, Mehlman CT, Slovek RW. The fate of untreated developmental dislocation of the hip: long-term follow-up of eleven patients. J Pediatr Orthop. 1999 Sep-Oct;19(5):641-4.
9. Vallamshetla VRP, Mughal E, O'Hara JN. Congenital dislocation of the hip—a re-appraisal of the upper age limit for treatment. J Bone Joint Surg Br. 2006;88(8):1076-81.
10. Schoenecker P, Strecker WB. Congenital dislocation of the hip in children: comparison of the effects of femoral shortening and of skeletal traction in treatment. J Bone Joint Surg Am. 1984;66(1):21-7.
11. Klisic P, Jankovic L. Combined procedure of open reduction and shortening of the femur in treatment of congenital dislocation of the hips in older children. Clin Orthop Relat Res. 1976;(119):60-9.
12. MacEwen GD. Treatment of congenital dislocation of the hip in older children. Clin Orthop Relat Res. 1987;(225):86-92.
13. Lai KA, Liu J, Liu TK. Use of iliofemoral distraction in reducing high congenital dislocation of the hip before total hip arthroplasty. J Arthroplasty. 1996;11(5):588-93.
14. Tönnis D. Normal values of the hip joint for the evaluation of x-rays in children and adults. Clin Orthop Relat Res. 1976;(119):39-47.
15. Acheson RM. The Oxford method of assessing skeletal maturity. Clin Orthop. 1957;10:19-39
16. Castaneda Leeder P, Haces Garcia F. [An analysis of healthy Mexican adolescents based on the guidelines provided by the Pediatric Orthopedic Society of North America]. Acta Ortop Mex. 2008;22(3):195-7.
17. Severin E. Contribution to the knowledge of congenital dislocation of the hip joint: late results of closed reduction and arthrographic studies of recent cases. Acta Chir Scand. 1941;84(Suppl 63):1-142.
18. Tönnis D. Normal values of the hip of the hip joint for the evaluation of x-rays in children and adults. Clin Orthop Relat Res. 1976;(119):39-47.
19. Weinstein SL. Natural history and treatment outcomes of childhood hip disorders. Clin Orthop Relat Res. 1997;(344):227-42.
20. Somerville EW. Long-term follow-up of congenital dislocation of the hip. J Bone Joint Surg Br. 1978;60(1):25-30.
21. Crawford AH, Mehlman CT, Slovek RW. Fate of the untreated congenitally dislocated hip: long-term follow-up of eleven patients. J Pediatr Orthop. 1999;19(2):641-4.
22. Salter RB, Dubos JP. The first fifteen year's personal experience with innominate osteotomy in the treatment of congenital dislocation and subluxation of the hip. Clin Orthop Relat Res. 1974;(98):72-103.
23. Karakas ES, Baktir A, Argün M, Türk CY. One-stage treatment of congenital dislocation of the hip in older children. J Pediatr Orthop. 1995;15(3):330-6.
24. Hartofilakidis G, Stamos K, Ioannidis TT. Low friction arthroplasty for old untreated congenital dislocation of the hip. J Bone Joint Surg Br. 1988;70(2):182-6.
25. Weinstein SL. Natural history of congenital hip dislocation (CDH) and hip dysplasia. Clin Orthop Relat Res. 1987;(225):62-76.
26. Massie WK, Howorth MB. Congenital dislocation of the hip: part II: results of open reduction as seen in early adult period. J Bone Joint Surg Am. 1951;33A(1):171-90.