



# The Interplay of Biomechanical and Biological Changes Following Meniscus Injury

Patrick X. Bradley<sup>1</sup> · Karl N. Thomas<sup>2</sup> · Avery L. Kratzer<sup>3</sup> · Allison C. Robinson<sup>2</sup> · Jocelyn R. Wittstein<sup>2</sup> · Louis E. DeFrate<sup>1,2,3</sup> · Amy L. McNulty<sup>2,3,4</sup> 

Accepted: 31 October 2022 / Published online: 7 December 2022

© The Author(s), under exclusive licence to Springer Science+Business Media, LLC, part of Springer Nature 2022

## Abstract

**Purpose of Review** Meniscus injury often leads to joint degeneration and post-traumatic osteoarthritis (PTOA) development. Therefore, the purpose of this review is to outline the current understanding of biomechanical and biological repercussions following meniscus injury and how these changes impact meniscus repair and PTOA development. Moreover, we identify key gaps in knowledge that must be further investigated to improve meniscus healing and prevent PTOA.

**Recent Findings** Following meniscus injury, both biomechanical and biological alterations frequently occur in multiple tissues in the joint. Biomechanically, meniscus tears compromise the ability of the meniscus to transfer load in the joint, making the cartilage more vulnerable to increased strain. Biologically, the post-injury environment is often characterized by an increase in pro-inflammatory cytokines, catabolic enzymes, and immune cells. These multi-faceted changes have a significant interplay and result in an environment that opposes tissue repair and contributes to PTOA development. Additionally, degenerative changes associated with OA may cause a feedback cycle, negatively impacting the healing capacity of the meniscus.

**Summary** Strides have been made towards understanding post-injury biological and biomechanical changes in the joint, their interplay, and how they affect healing and PTOA development. However, in order to improve clinical treatments to promote meniscus healing and prevent PTOA development, there is an urgent need to understand the physiologic changes in the joint following injury. In particular, work is needed on the *in vivo* characterization of the temporal biomechanical and biological changes that occur in patients following meniscus injury and how these changes contribute to PTOA development.

**Keywords** Post-traumatic osteoarthritis · Cartilage · Mechanics · Loading · Inflammation · Repair

---

This article is part of the Topical Collection on *Osteoarthritis*

---

Patrick X. Bradley and Karl N. Thomas both contributed equally.

---

Louis E. DeFrate and Amy L. McNulty both contributed equally.

---

✉ Amy L. McNulty  
alr@duke.edu

<sup>1</sup> Department of Mechanical Engineering and Materials Science, Duke University, Durham, NC, USA

<sup>2</sup> Department of Orthopaedic Surgery, Duke University School of Medicine, DUMC Box 3093, Durham, NC 27710, USA

<sup>3</sup> Department of Biomedical Engineering, Duke University, Durham, NC, USA

<sup>4</sup> Department of Pathology, Duke University School of Medicine, Durham, NC, USA

## Introduction

The menisci are a pair of crescent-shaped, concave, fibrocartilaginous tissues that sit between the femoral condyles and tibial plateaus. Once considered vestigial structures, the menisci are now known to be important for maintaining joint health and stability [1, 2]. Meniscus injuries are extremely common, with over 850,000 meniscus surgeries performed each year in the USA and approximately 2 million worldwide [3, 4]. Patients with minor meniscus tears are 3-times more likely to develop post-traumatic osteoarthritis (PTOA) than patients with healthy menisci, and the number increases nearly eightfold in cases of severe meniscal damage among individuals 50–79 years old [5]. However, the factors that contribute to PTOA development still remain unclear. Therefore, the purpose of this review is to outline the current understanding of biomechanical and biological repercussions following meniscus injury and how these

changes impact meniscus repair and PTOA development. Moreover, we identify key gaps in knowledge that must be further investigated to improve meniscus healing and prevent PTOA.

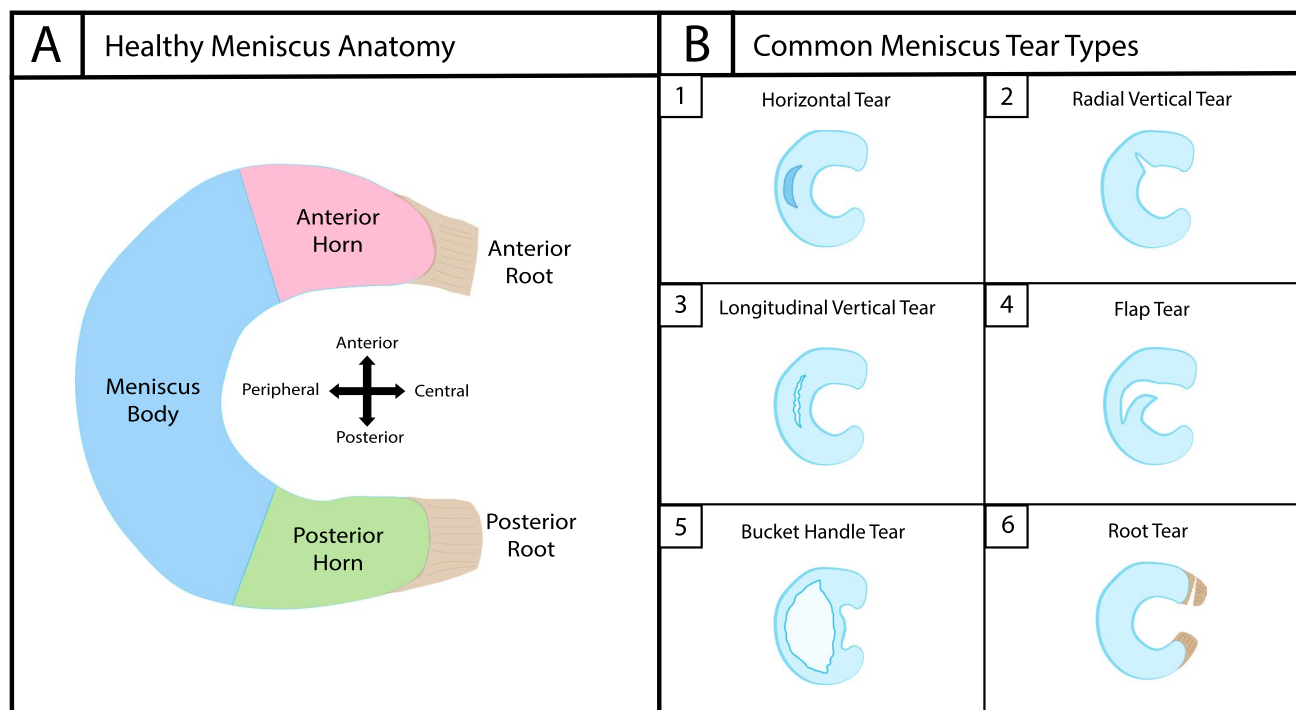
## Role of the Menisci in the Joint and Post-Traumatic Osteoarthritis (PTOA) Development

Functionally, the menisci provide joint congruity, promote stability, and serve to transmit and distribute loads between the femoral and tibial cartilage surfaces [2, 6]. During joint loading, the menisci are compressed, and due to the concave shape of the tissue, a horizontal component of this force is exerted radially on each meniscus [2, 7]. This outward radial stress is countered by inward pull from the posterior and anterior horns that anchor the menisci to the tibial plateau via the meniscal roots (Fig. 1A). The menisci are primarily comprised of circumferentially oriented collagen fibers with interwoven radial fibers. This ECM structure provides

resistance to compressive, shear, and tensile forces, allowing the menisci to stabilize the knee under various loading conditions [2].

Combined, the medial and lateral menisci increase the tibiofemoral contact area by over 50%, as compared to a joint without meniscal tissue [8]. Expanding contact area allows for greater congruency between the femoral and tibial joint surfaces, distributing load, and ultimately decreasing contact stress on the articular cartilage [9]. One study utilizing a cadaveric model with thin film pressure sensors found that the medial meniscus transmits between 40 and 80% of the load across the knee [10]. Furthermore, an in vivo study using magnetic resonance (MR) imaging found that in healthy knees, cartilage covered by the medial meniscus experiences significantly less strain in response to dynamic activity than the adjacent uncovered cartilage [11]. This highlights the importance of the menisci in maintaining normal cartilage loading and cartilage health [5].

Meniscus lesions can be classified as either degenerative or traumatic. Degenerative meniscal tears involve progressive erosion of the tissue, while traumatic tears



**Fig. 1** **A** Depicts the major regions of the healthy meniscus, including the meniscus body, anterior horn, posterior horn, anterior root, and posterior root. **B** Depicts six of the major meniscus tear types. **B1** Horizontal tears occur between the superior and inferior surfaces of the meniscus parallel to the tibial plateau. **B2** Radial vertical tears occur perpendicular to the tibial plateau and progress across the circumferential fibers of the meniscus. **B3** Longitudinal vertical tears occur perpendicular to the tibial plateau and develop along the cir-

cumferential fibers of the meniscus. **B4** Flap tears occur when either a vertical or horizontal tear progresses until there is a displaced "flap" of meniscus tissue. **B5** Bucket handle tears are longitudinal tears that form in either the body of the meniscus or at the periphery of the body and posterior horn and flip or fold over into the central aspect of the knee, resembling a bucket handle attached at the anterior and posterior aspects. **B6** Meniscus root tears occur at or within 1 cm of the meniscus root attachment and are most commonly radial tears

are the result of acute knee injury and are more common in younger, athletic populations [12]. Tears are classified according to injury morphology (Fig. 1B). Meniscal tears that occur parallel to the tibial plateau are referred to as horizontal tears, while tears that occur perpendicular to the tibial plateau are referred to as vertical tears [13, 14]. Vertical tears can either be radial, meaning they occur across the circumferential fibers of the meniscus [15], or longitudinal, meaning they develop along the circumferential fibers of the meniscus [16]. Flap tears typically progress from either vertical or horizontal tears when a portion of the meniscus partially detaches or folds over [13, 14]. Bucket handle tears are longitudinal tears that form in either the body of the meniscus or at the periphery of the body and posterior horn and flip or fold over into the central aspect of the knee, resembling a bucket handle attached at the anterior and posterior aspects [17]. Meniscus root tears occur at or within 1 cm of the meniscus root attachment and are most commonly radial tears [18]. Finally, complex tears exhibit two or more tear patterns simultaneously [13, 14]. Complex and horizontal tears tend to be degenerative, while vertical tears occur more frequently as a result of acute injury [19–21]. Furthermore, medial meniscus injuries are approximately three times more prevalent than lateral meniscus injuries, possibly due to the fact that the medial meniscus is more firmly attached to the joint [1, 22, 23].

Treatments for meniscal tears include non-operative management, meniscal repair, or partial meniscectomy [24]. Clinicians typically assess patient factors (e.g., age, joint health, and comorbidities) along with characteristics of the tear (e.g., location and severity) to determine which approach is best for a given injury. While for many years meniscectomy was standard practice, research has since highlighted the role of the menisci in load distribution and joint stability. Furthermore, in the long term, meniscectomy leads to PTOA development [5, 24]. Thus, treatment approaches have shifted to prioritize the preservation of the menisci. Repair of tears located in the vascularized outer zone yield the highest success rates and most significant improvements to patient-reported outcomes [25]. In contrast, tears in the avascular inner zone of the menisci demonstrate limited healing [26, 27]. When meniscal repair surgery is not feasible or fails, partial meniscectomy is often the next best option [28]. However, while partial meniscectomy yields short-term improvements in symptoms and pain, even a small loss of meniscus tissue may lead to long-term increases in cartilage degradation and PTOA [29–31]. Of patients who undergo meniscectomy, about 50% will develop PTOA within 10–20 years, a relative risk ten-times greater than a healthy reference population [31]. Likewise, a failed meniscus repair is associated with a five-fold increased risk for PTOA development [32•].

## Biomechanical Changes Following Meniscus Injury

One of the proposed links between meniscus injury and PTOA development is altered joint biomechanics resulting from meniscus injury. Significant damage to or loss of the meniscus can greatly impact the ability of the tissue to resist deformation and transmit load [33, 34]. For example, cadaveric studies have estimated that removal of the medial meniscus can increase contact stress between the articulating cartilage surfaces by 100% and that removal of the lateral meniscus can increase contact stress by 200–300% [35]. The resultant biomechanical changes due to meniscus injury occur through a variety of avenues, ranging from altered mechanical properties of the meniscus to abnormal joint- and tissue-level loading [36–38]. Additionally, the heterogeneity of meniscus injuries makes it difficult to identify a single set of characteristic biomechanical changes post-injury. However, several joint changes are commonly reported following meniscus injury, including increased meniscus extrusion and increased peak contact pressures [38–40].

Meniscus extrusion, traditionally measured as the distance the meniscus protrudes beyond the tibial plateau, is often associated with meniscus injuries and progressive joint degeneration. When a meniscus is torn or injured, stress along the circumferentially-oriented collagen fibers, referred to as hoop stress, is disrupted, making the meniscus more susceptible to extrusion [41, 42]. Using MR imaging, investigators have found that meniscal root tears and severe tears to the body of the meniscus are predictors of abnormally high extrusion [39, 43, 44•]. Meniscus extrusion may be problematic because it leaves the articular cartilage more susceptible to higher contact stresses. Furthermore, several studies have found that meniscus extrusion is significantly greater in knees with osteoarthritis (OA) compared to healthy control knees [42, 45, 46].

Changes to the local mechanical environment of the menisci and articulating cartilage surfaces are also commonly reported following meniscal injury. These changes may be due in part to meniscus extrusion leading to decreased joint congruity and increased cartilage-to-cartilage contact [39, 42, 45]. However, even in the absence of extrusion, the local mechanical environment is altered due to a decreased ability of the meniscus to resist deformation and transmit load when injured [33, 34]. Cadaveric studies using thin film pressure sensors show that partial tears of either the medial or lateral meniscus can result in significant increases in peak contact pressures [38, 47]. Similarly, in an ex vivo large animal model, destabilization of the medial meniscus results in significant increases in peak contact pressures and decreases in contact areas

1 month after injury [48•]. While these studies provide valuable information, it is difficult to translate *ex vivo* models of loading to *in vivo* conditions; therefore, studies characterizing *in vivo* changes in the biomechanics of the joint following meniscus injury are needed. One such *in vivo* study utilized a combination of biplanar radiography and MR imaging to compare cartilage contact strains between healthy and injured knees in patients with a unilateral medial meniscus tear [49]. Specifically, this study found increased contact strains in both the medial and lateral compartments of the injured knee compared to the healthy knee [49]. Additionally, a recent *in vivo* study used pressure sensors to measure the intraoperative peak contact pressure differences between meniscectomized and allograft-implanted knees [50]. After the allograft was implanted, the mean peak contact pressure decreased by 19% [50]. These results indicate that meniscal injuries are likely to produce a mechanical environment characterized by decreased tibiofemoral contact areas, increased peak cartilage and meniscus stresses, and increased cartilage strain and meniscus deformation.

Current rehabilitation strategies after meniscal surgery vary widely depending on the type of meniscus tear and the strategy recommended by the surgeon and physical therapist. Important considerations of post-operative care are the extent to which knee flexion and weight-bearing should be allowed and the timing of these activities [51]. These decisions are hindered by the lack of data describing how the meniscus is loaded *in vivo*, thus making it difficult to know what activities are beneficial or detrimental. These factors play a critical role in the success of rehabilitation programs due to the role that mechanical loading plays in meniscus healing [52]. Understanding how the meniscus is loaded *in vivo* and finding loading regimes that maximize healing potential is crucial to the success of meniscus repair and prevention of further joint degradation.

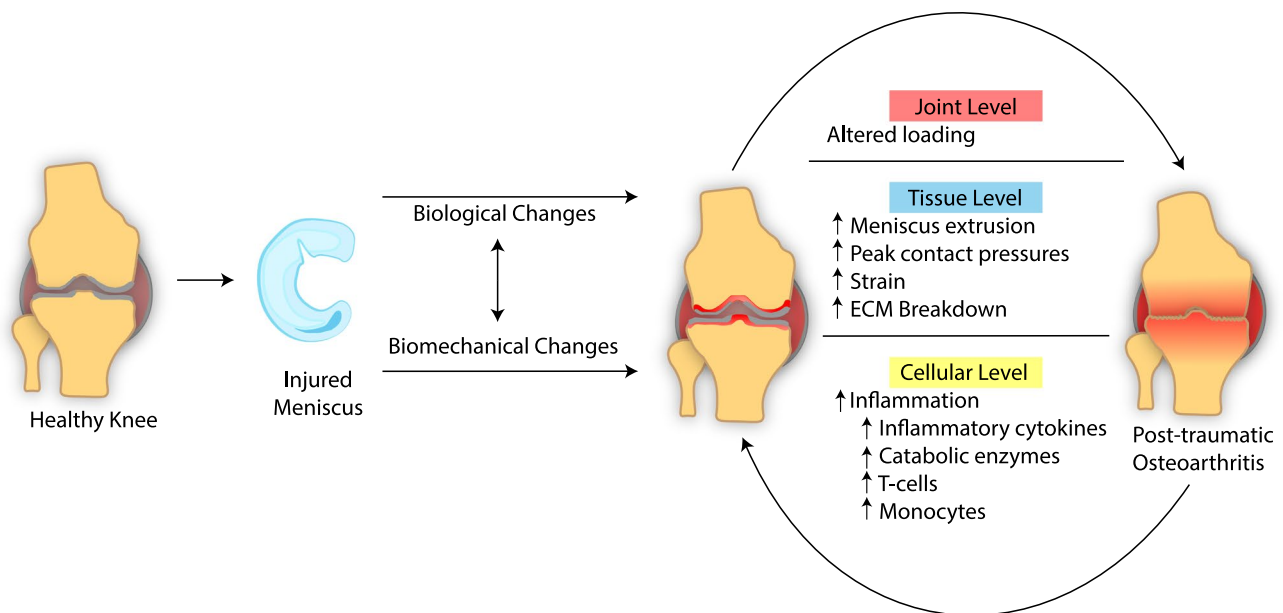
Loading of meniscus tissue may be beneficial for repair [52, 53•]. However, the meniscus is subjected to a variety of mechanical loads [52]. During activities of daily living, the magnitudes of these loads vary both temporally and spatially throughout the meniscus. Furthermore, the meniscus is heterogeneous, with cell types, ECM structure, and vascularity varying substantially throughout the tissue. Thus, it is difficult to identify a precise loading regime that optimally promotes healing. There have been significant strides made towards accomplishing this goal through understanding how mechanical loading influences inflammation-related tissue degradation [53•]. There is evidence to suggest that static loading and high levels of strain promote breakdown of the ECM *ex vivo* and *in vitro* [54, 55]. In contrast, numerous studies show that certain levels of cyclic loading may actually stimulate meniscal repair through reduction of pro-inflammatory mediators and increased anabolism [53•, 56–64]. Therefore, it is thought that

dynamic loading within an appropriate range of magnitudes, frequencies, and durations may enhance repair, while loading outside this range may inhibit repair and promote meniscus degradation. However, it is difficult to translate *ex vivo* and *in vitro* mechanical and biological conditions to the *in vivo* joint environment. Thus, there is a significant need for more *in vivo* work to clarify the relationship between loading and inflammation and determine optimal bounds for loading conditions to promote healing. This work is particularly important in an injured population where disruption to normal loading of the knee potentially leads to hyperphysiologic strain and presents inherent challenges to the repair of the meniscus. To this point, in a meniscus-injured population, Carter et al. found a correlation between cartilage strain and total matrix metalloproteinase (MMP) activity, a biomarker related to ECM catabolism. This indicates a significant link between *in vivo* cartilage and meniscus mechanical function and the catabolic response within the joint [49]. However, much work still remains to determine optimal loading regimes to promote healing.

In addition to the interplay between biological and biomechanical factors following injury, there is also a feedback cycle between OA and meniscus health (Fig. 2). In individuals with knee OA, changes to gait patterns are common and may include reduced range of motion, increased ground reaction forces, and increased knee adduction moments, which are likely to place abnormal stresses on the menisci [65–67]. In addition to joint level changes, tissue mechanical properties are likely to deteriorate with OA as well. In particular, articular cartilage with OA is less resistant to compressive loading and takes longer to recover from mechanical loading compared to healthy cartilage [68, 69]. Furthermore, a recent study using finite element analysis modeled alterations in cartilage geometry and mechanical properties consistent with medial compartment knee OA and found that hoop stresses increase significantly in the posterior region of the medial meniscus [70]. Other studies have shown that meniscus mechanical properties are also altered by OA status [71, 72]. These findings are consistent with prior studies reporting that degenerative meniscal tears are associated with previous OA diagnoses and that OA-driven mechanical changes may contribute to degenerative meniscus tears [73, 74]. These changes may further inhibit meniscus healing, thereby causing a feedback cycle between meniscus injuries, healing, and PTOA.

## Biological Changes Following Meniscus Injury

In addition to biomechanical changes, there are also biological changes in the joint following meniscus injury. An elevated and prolonged inflammatory response is commonly



**Fig. 2** A multitude of changes at the joint, tissue, and cellular levels act to inhibit the repair of the meniscus through biomechanical and biological avenues

associated with a meniscus injury. Within the first 24 h following an acute knee injury, concentrations of interleukin (IL)-1 $\beta$ , IL-6, and tumor necrosis factor- $\alpha$  (TNF- $\alpha$ ) are increased in the synovial fluid [75]. In patients, 3 or more months post-injury, concentrations of IL-6, IL-8, TNF- $\alpha$ , and IL-10 are higher in injured knees compared to normal knees, while IL-1 receptor antagonist (IL-1Ra) and IL-1 $\beta$  are significantly lower [76]. Interestingly, concentrations of IL-6 continue to be elevated 12.5-fold at 18 months post-injury [77•]. By comparison, in a surgically-induced longitudinal tear model in rabbits, IL-1 $\alpha$  immunostaining of the femoral surface of the meniscus peaks within 24 h of surgery and decreases rapidly between 14 and 28 days [78]. Consistent with this finding, prior work shows that the IL-1 $\alpha$  isoform is more prominent in early inflammation compared to IL-1 $\beta$  [79, 80]. Despite not displaying the same longevity in the injured joint compared to other inflammatory cytokines, IL-1 inhibits *in vitro* integrative meniscus repair more potently than TNF- $\alpha$  at equivalent concentrations [80]. Furthermore, an acute 3-day exposure to physiologic concentrations of IL-1 $\alpha$  has long-lasting effects, causing catabolism of meniscus tissue and preventing meniscus tissue repair for at least 28 days [81].

These inflammatory cytokines are prominent regulators of numerous catabolic enzymes, including MMPs. The collagenases MMP-1, MMP-8, MMP-13, and membrane type 1 MMP can cleave the intact triple helical collagen fibrils into one-quarter and three-quarter length fragments [82], which are subsequently degraded by other MMPs, such as MMP-2 and MMP-9 [83]. MMPs are upregulated following

meniscus injury [84, 85]. In addition, they are also mechanically regulated [86] and dose-dependently increased by IL-1 [87, 88]. Total MMP activity is increased approximately 25-fold in the synovial fluid of knees with a meniscus tear compared to control knees [89]. Additionally, in patients with a meniscus injury, there is a positive correlation between cartilage strain during weight-bearing knee flexion in the injured knee and total MMP activity in the synovial fluid [49]. Total MMP activity is also positively correlated with levels of the pro-inflammatory mediator prostaglandin E2 (PGE2) in the synovial fluid of meniscus-injured knees an average of 10.8 weeks from injury [81]. Likewise, synovial fluid PGE2 concentrations are elevated 290-fold in meniscus-injured knees compared to control knees [89]. PGE2 plays a role in inflammation, apoptosis, and OA structural changes [90, 91]. Therefore, the upregulation in MMP activity and PGE2 in response to meniscal injury leads to an enhanced pro-inflammatory and catabolic environment that may contribute to PTOA development [89].

Further nuance is added by the fact that biological changes in response to meniscus injury are influenced by the tear type, location of the tear, and proximity to the tear. Bucket handle tears result in significantly higher synovial fluid TNF- $\alpha$  levels compared to tears in the posterior horn [92•]. On the other hand, posterior horn tears result in significantly higher levels of IL-1 $\beta$  compared to bucket handle tears [92•]. Similarly, complex medial meniscus tears are associated with significantly more MMP-10 in the synovial fluid compared to other tear types (horizontal, complex lateral, and bucket handle tears) [89]. In contrast, serum from

patients with complex medial tears contains significantly less IL-8 and TNF- $\alpha$  compared to serum from patients with other tear types [89]. At the gene expression level, MMP-1 is higher in traumatic tears than in degenerative tears [93]. Likewise, the expression of TNF- $\alpha$  and IL-6 is elevated in meniscus tissue adjacent to the tear site, as compared to tissue that is further from the site of injury [94]. This variability in the cytokine response may be a result of heterogeneity within the meniscus, with differences in cell phenotype, ECM composition, vascularity, and mechanical loading in different regions of the meniscus [53•]. Furthermore, interpretation of *in vivo* biomarker data can also be challenging due to the fact that meniscus tears are frequently associated with damage to other joint tissues, including the anterior cruciate ligament (ACL) [95]. Therefore, it may be important to study the biological responses between patients with different patterns of injuries in order to identify injury-specific biomarkers.

Cytokines upregulated in the joint following meniscus injury may influence meniscus repair and PTOA development. In the synovial fluid of meniscus-injured patients, there is a significant positive correlation between TNF- $\alpha$  concentration and joint degeneration, as assessed by the MRI OA Knee Score (MOAKS) [96]. Similarly, in porcine synovial fluid, both IL-1 $\alpha$  and IL-1 $\beta$  concentrations are positively correlated with the degree of meniscal degeneration assessed using a macroscopic grading scale [88]. This relationship between inflammatory cytokines and degeneration also extends to meniscus repair, which is stifled by increased concentrations of both IL-1 and TNF- $\alpha$  [97]. Both of these cytokines independently suppress *in vitro* healing by inhibiting cellular proliferation, decreasing the shear strength of repair, and preventing tissue healing at the site of injury [97]. This reported inhibition of proliferation aligns with *in vivo* research showing that hepatocyte growth factor (HGF), an inhibitor of mitogenesis, is significantly higher in the synovial fluid of patients with a failed meniscus repair compared to those with a successful outcome [98]. In addition to the effects on cellular proliferation, IL-1 upregulates MMP activity, increases nitric oxide (NO) production, and promotes sulfated glycosaminoglycan (sGAG) release from meniscus tissue, all of which contribute to the suppression of meniscus tissue repair [60, 81]. In contrast, inhibition of IL-1 using IL-1Ra or inhibition of TNF- $\alpha$  using monoclonal antibodies restores both cellular accumulation at the defect site and interfacial shear strength in a porcine meniscus repair model [80]. While clinical applications of IL-1Ra have been unsuccessful at ameliorating OA progression [99], the efficacy of IL-1Ra on meniscus healing in patients is currently unknown. Therefore, further work is needed to paint a comprehensive picture of how biological changes following meniscus injury impact tissue healing and disease progression in patients.

IL-1 and TNF- $\alpha$  are also associated with increased apoptosis in meniscus and OA models. In the case of TNF- $\alpha$ , apoptosis can occur via direct stimulation of death receptors [100]. On the other hand, IL-1 dose-dependently increases NO production [87, 88, 101], which results in diminished phosphorylation of Jun-N-terminal-Kinase (JNK), suppressed autophagy, and increased apoptosis. [102]. Inhibition of nitric oxide synthase (NOS) in meniscal cells increases autophagy and curtails apoptosis. Additionally, NOS inhibition reduces MMP and aggrecanase expression, which are key mediators of ECM degradation [102]. Therefore, inhibition of the NO pathway may be another means for therapeutic intervention to enhance meniscus repair.

IL-1 also promotes ECM degradation by upregulating MMP activity [81]. For *in vitro* meniscus repair model systems, IL-1 exposure dose-dependently suppresses the shear strength of repair in explant models [80, 81, 103]. Furthermore, MMP activity is significantly elevated following chronic IL-1 exposure compared to acutely exposed or unexposed tissue explants. This indicates that MMP-induced ECM degradation may be suppressing repair [81]. To this point, there is an increase in synovial fluid MMP-2 in patients with failed meniscus repair relative to those with successful repair [98]. Furthermore, treatment of porcine meniscus repair model explants with a broad spectrum MMP inhibitor partially blocks IL-1-induced suppression of meniscus repair [104]. Given that total MMP activity is elevated in meniscus-injured knees [89], these enzymes provide another potential therapeutic target to enhance meniscus healing and prevent PTOA development.

While numerous studies have investigated changes in cytokine and catabolic biomarkers, immune cell profiles in the joint following meniscus injury are less well-characterized. Synovial fluid from knees with ACL, meniscus, or combined ACL and meniscus injuries contain more total viable cells and CD3+ T cells than the synovial fluid of matched contralateral healthy knees [105•]. This study reveals that meniscus injury leads to an immune cell-rich joint environment that consists largely of T cells, with multiple T-helper phenotypes [105•]. These immune cell profiles are similar to findings in patients with advanced stages of OA and rheumatoid arthritis [106–108]. Therefore, immune cells may be modulators of joint changes after meniscus injury that contribute to the development of PTOA. However, much work is still needed to understand the time course of immune cell changes after meniscus injury and the role of these cells in joint degeneration.

Additionally, synovial fluid aspirated from ACL-, meniscus-, or both ACL- and meniscus-injured knees reveals that, while not significant, on average there are higher numbers of pre-monocytes, monocytes, classical monocytes, intermediate monocytes, and activated monocytes in the synovial fluid of the injured knees compared to contralateral healthy

knees [105•]. Under inflammatory conditions, circulating monocytes may migrate into the joint space and differentiate into macrophages and dendritic cells [109]. Therefore, the presence of monocytes in injured joints may be a sign of early inflammation. In OA patients, approximately 75% of knees are positive for active macrophages, with a significant positive correlation between radiographic OA severity and the number of macrophages [110]. These findings suggest that macrophages may play a role in OA progression. However, the role of macrophages in inflammation and PTOA development after meniscus injury remains unclear. Macrophages are commonly characterized as pro-inflammatory (M1) or anti-inflammatory (M2), with a higher ratio of M1 to M2 macrophages potentially contributing to OA development [111]. The elevation of monocytes following meniscus injury suggests that these cells may be migrating into the joint and differentiating into M1 macrophages that can release inflammatory cytokines, namely IL-1, IL-6, IL-12, and TNF- $\alpha$  [112]. These changes may prolong the inflammatory response and contribute to the development of PTOA. Depletion of CD14+ macrophages from OA synovial cells in culture not only eliminates the production of IL-1 $\beta$  and TNF- $\alpha$  but also hampers the production of IL-6 and IL-8 and downregulates MMP-1 and MMP-3 [113]. However, depletion of M1 and M2 macrophages has not been shown to mitigate PTOA in murine models of destabilization of the medial meniscus [114] or articular fracture [115]. Rather, these studies found an increase in infiltration of CD3+ T cells and neutrophils into the joint and enhanced synovitis, suggesting a compensatory effect following macrophage depletion. On the other hand, following meniscectomy, meniscus healing is observed in mice treated with stromal cell-derived factor-1 $\alpha$  (SDF-1 $\alpha$ ), which enhances the migration of macrophages to the site of injury and promotes macrophage polarization towards the M2 phenotype [116]. Similarly, knockout of macrophage migration inhibitory factor (MIF) in mice results in improved joint health and reduced OA development compared to wild-type controls [117]. These studies suggest that further characterization of the spectrum of immune cell populations and their roles following joint injury is needed.

## Conclusions

In recent years, increased appreciation has been paid to the menisci for their critical role in maintaining knee function. Although advancements have been made towards treatment strategies that preserve meniscus tissue integrity and function, outcomes for the repair of the inner zone of the meniscus remain poor and the risk for PTOA development following meniscus injury remains high. Healing

of the meniscus is inherently challenged by injury-driven changes. A multitude of changes at the joint, tissue, and cellular levels act to inhibit the repair of the meniscus through both biomechanical and biological avenues. Biomechanically, meniscus tears frequently lead to increased meniscus extrusion and altered stresses and strains in the joint. These aberrations in mechanical loading result in the upregulation of pro-inflammatory and catabolic factors, which hinder meniscus healing. Biologically, meniscus tears often lead to an upregulation of inflammatory cytokines, such as IL-1, IL-6, and TNF- $\alpha$ , an increase in catabolic enzymes, such as MMPs, an increase in T cells, and potentially increases in monocytes. These changes broadly promote inflammation and breakdown of the ECM, which results in decreased mechanical properties of the tissue, as well as suppression of cellular proliferation and repair. The two-pronged disruption of both biomechanical and biological homeostasis leads to a positive feedback cycle, whereby each factor reinforces the degeneration spurred by the other, resulting in a sustained environment that hinders tissue repair (Fig. 2). While increased stress and inflammation are potentially strong contributors to PTOA development, compromised meniscus function further amplifies degeneration of the articulating cartilage surfaces. Altered stress and strain distributions in both the cartilage and meniscus potentially trigger inflammation and a cascade of catabolic mediators. Additionally, OA-associated changes in the mechanical properties and morphology of cartilage and meniscus lead to a feedback cycle that further stifles meniscus healing. While much work has been devoted to understanding post-injury biomechanical and biological changes, as well as how loading regulates the inflammatory response of the joint, this work has largely been performed in *ex vivo* and *in vitro* environments. Thus, more *in vivo* data is needed in patients to better understand the primary mechanisms driving failed meniscus repair and joint degeneration following meniscus injury. Understanding these degenerative processes is necessary to develop new treatments and novel avenues for promoting meniscus healing, mitigating joint degeneration, and preventing PTOA progression.

**Funding** This paper was funded in part by NIH grants AR079184, AR065527, AR074800, AR078245, and AR073221.

## Compliance with Ethical Standards

**Conflict of Interest** The authors declare no competing interests.

**Human and Animal Rights and Informed Consent** All reported studies/experiments with human or animal subjects performed by the authors have been previously published and complied with all applicable ethical standards.

## References

Papers of particular interest, published recently, have been highlighted as:

• Of importance

- Fairbank TJ. Knee joint changes after meniscectomy. *J Bone Joint Surg Br.* 1948;30B(4):664–70.
- Makris EA, Hadidi P, Athanasiou KA. The knee meniscus: structure-function, pathophysiology, current repair techniques, and prospects for regeneration. *Biomaterials.* 2011;32(30):7411–31. <https://doi.org/10.1016/j.biomaterials.2011.06.037>.
- American Orthopaedic Society for Sports Medicine AAOS. OKU Orthopaedic Knowledge Update: Sports medicine 2. American Academy of Orthopaedic Surgeons: University of Michigan; 1999.
- Adams BG, Houston MN, Cameron KL. The epidemiology of meniscus injury. *Sports Med Arthrosc Rev.* 2021;29(3):e24–33. <https://doi.org/10.1097/JSA.0000000000000329>.
- Englund M, Guermazi A, Roemer FW, Aliabadi P, Yang M, Lewis CE, et al. Meniscal tear in knees without surgery and the development of radiographic osteoarthritis among middle-aged and elderly persons: the Multicenter Osteoarthritis Study. *Arthritis Rheum.* 2009;60(3):831–9. <https://doi.org/10.1002/art.24383>.
- Levy IM, Torzilli PA, Warren RF. The effect of medial meniscectomy on anterior-posterior motion of the knee. *J Bone Joint Surg Am.* 1982;64(6):883–8.
- Fox AJ, Bedi A, Rodeo SA. The basic science of human knee menisci: structure, composition, and function. *Sports Health.* 2012;4(4):340–51. <https://doi.org/10.1177/1941738111429419>.
- Fukubayashi T, Kurosawa H. The contact area and pressure distribution pattern of the knee. A study of normal and osteoarthrotic knee joints. *Acta Orthop Scand.* 1980;51(6):871–9. <https://doi.org/10.3109/17453678008990887>.
- Walker PS, Erkman MJ. The role of the menisci in force transmission across the knee. *Clin Orthop Relat Res.* 1975;109:184–92. <https://doi.org/10.1097/00003086-197506000-00027>.
- Walker PS, Arno S, Bell C, Salvatore G, Borukhov I, Oh C. Function of the medial meniscus in force transmission and stability. *J Biomech.* 2015;48(8):1383–8. <https://doi.org/10.1016/j.jbiomech.2015.02.055>.
- Liu B, Lad NK, Collins AT, Ganapathy PK, Utturkar GM, McNulty AL, et al. In vivo tibial cartilage strains in regions of cartilage-to-cartilage contact and cartilage-to-meniscus contact in response to walking. *Am J Sports Med.* 2017;45(12):2817–23. <https://doi.org/10.1177/0363546517712506>.
- Greis PE, Bardana DD, Holmstrom MC, Burks RT. Meniscal injury: I. Basic science and evaluation. *J Am Acad Orthop Surg.* 2002;10(3):168–76. <https://doi.org/10.5435/00124635-200205000-00003>.
- Binfield PM, Maffulli N, King JB. Patterns of meniscal tears associated with anterior cruciate ligament lesions in athletes. *Inj.* 1993;24(8):557–61. [https://doi.org/10.1016/0020-1383\(93\)90038-8](https://doi.org/10.1016/0020-1383(93)90038-8).
- Maffulli N, Chan KM, Bundoc RC, Cheng JC. Knee arthroscopy in Chinese children and adolescents: an eight-year prospective study. *Arthrosc.* 1997;13(1):18–23. [https://doi.org/10.1016/s0749-8063\(97\)90205-x](https://doi.org/10.1016/s0749-8063(97)90205-x).
- De Smet AA, Norris MA, Yandow DR, Quintana FA, Graf BK, Keene JS. MR diagnosis of meniscal tears of the knee: importance of high signal in the meniscus that extends to the surface. *AJR Am J Roentgenol.* 1993;161(1):101–7. <https://doi.org/10.2214/ajr.161.1.8517286>.
- Jee WH, McCauley TR, Kim JM, Jun DJ, Lee YJ, Choi BG, et al. Meniscal tear configurations: categorization with MR imaging. *AJR Am J Roentgenol.* 2003;180(1):93–7. <https://doi.org/10.2214/ajr.180.1.1800093>.
- Shakespeare DT, Rigby HS. The bucket-handle tear of the meniscus. A clinical and arthrographic study. *J Bone Joint Surg Br.* 1983;65(4):383–7. <https://doi.org/10.1302/0301-620X.65B4.6874707>.
- Pache S, Aman ZS, Kennedy M, Nakama GY, Moatshe G, Ziegler C, et al. Meniscal root tears: current concepts review. *Arch Bone Jt Surg.* 2018;6(4):250–9.
- Poehling GG, Ruch DS, Chabon SJ. The landscape of meniscal injuries. *Clin Sports Med.* 1990;9(3):539–49.
- Aichroth P. Degenerative meniscal tears. *Knee.* 1994;1(3):133–84.
- Englund M. Meniscal tear—a feature of osteoarthritis. *Acta Orthop Scand.* 2004;75(sup312):1–45. <https://doi.org/10.1080/03008820410002048>.
- Baker BE, Peckham AC, Puppato F, Sanborn JC. Review of meniscal injury and associated sports. *Am J Sports Med.* 1985;13(1):1–4. <https://doi.org/10.1177/036354658501300101>.
- Thompson WO, Thaete FL, Fu FH, Dye SF. Tibial meniscal dynamics using three-dimensional reconstruction of magnetic resonance images. *Am J Sports Med.* 1991;19(3):210–5. <https://doi.org/10.1177/036354659101900302>.
- Karia M, Ghaly Y, Al-Hadithy N, Mordecai S, Gupta C. Current concepts in the techniques, indications and outcomes of meniscal repairs. *Eur J Orthop Surg Traumatol.* 2019;29(3):509–20. <https://doi.org/10.1007/s00590-018-2317-5>.
- Cinque ME, DePhillipo NN, Moatshe G, Chahla J, Kennedy MI, Dornan GJ, et al. Clinical outcomes of inside-out meniscal repair according to anatomic zone of the meniscal tear. *Orthop J Sports Med.* 2019;7(7):2325967119860806. <https://doi.org/10.1177/2325967119860806>.
- Barber FA, McGarry JE. Meniscal repair techniques. *Sports Med Arthrosc Rev.* 2007;15(4):199–207. <https://doi.org/10.1097/JSA.0b013e3181595bed>.
- DeHaven KE. Decision-making factors in the treatment of meniscus lesions. *Clin Orthop Relat Res.* 1990;252:49–54.
- Ronnblad E, Barenius B, Engstrom B, Eriksson K. Predictive factors for failure of meniscal repair: a retrospective dual-center analysis of 918 consecutive cases. *Orthop J Sports Med.* 2020;8(3):2325967120905529. <https://doi.org/10.1177/2325967120905529>.
- Williams RJ 3rd, Warner KK, Petrigliano FA, Potter HG, Hatch J, Cordasco FA. MRI evaluation of isolated arthroscopic partial meniscectomy patients at a minimum five-year follow-up. *HSS J.* 2007;3(1):35–43. <https://doi.org/10.1007/s11420-006-9031-2>.
- Papalia R, Del Buono A, Osti L, Denaro V, Maffulli N. Meniscectomy as a risk factor for knee osteoarthritis: a systematic review. *Br Med Bull.* 2011;99:89–106. <https://doi.org/10.1093/bmb/ldq043>.
- Lohmander LS, Englund PM, Dahl LL, Roos EM. The long-term consequence of anterior cruciate ligament and meniscus injuries: osteoarthritis. *Am J Sports Med.* 2007;35(10):1756–69. <https://doi.org/10.1177/0363546507307396>.
- Ronnblad E, Barenius B, Stalman A, Eriksson K. Failed meniscal repair increases the risk for osteoarthritis and poor knee function at an average of 9 years follow-up. *Knee Surg Sports Traumatol Arthrosc.* 2021. <https://doi.org/10.1007/s00167-021-06442-w>. (This longitudinal study found a 5-fold increase in risk for OA with a failed meniscus repair.)
- Yao J, Funkenbusch PD, Snibbe J, Maloney M, Lerner AL. Sensitivities of medial meniscal motion and deformation to material properties of articular cartilage, meniscus and meniscal



- attachments using design of experiments methods. *J Biomech Eng.* 2006;128(3):399–408. <https://doi.org/10.1115/1.2191077>.
34. Wojtys EM, Chan DB. Meniscus structure and function. *Instr Course Lect.* 2005;54:323–30.
  35. Fox AJS, Bedi A, Rodeo SA. The basic science of human knee menisci: structure, composition, and function. *Sports health.* 2012;4(4):340–51. <https://doi.org/10.1177/1941738111429419>.
  36. Nicolas R, Nicolas B, Francois V, Michel T, Nathaly G. Comparison of knee kinematics between meniscal tear and normal control during a step-down task. *Clin Biomech (Bristol, Avon).* 2015;30(7):762–4. <https://doi.org/10.1016/j.clinbiomech.2015.05.012>.
  37. Bansal S, Meadows KD, Miller LM, Saleh KS, Patel JM, Stoeckl BD, et al. Six-month outcomes of clinically relevant meniscal injury in a large-animal model. *Orthop J Sports Med.* 2021;9(11):23259671211035444. <https://doi.org/10.1177/23259671211035444>.
  38. Bedi A, Kelly NH, Baad M, Fox AJ, Brophy RH, Warren RF, et al. Dynamic contact mechanics of the medial meniscus as a function of radial tear, repair, and partial meniscectomy. *J Bone Joint Surg Am.* 2010;92(6):1398–408. <https://doi.org/10.2106/JBJS.I.00539>.
  39. Crema MD, Roemer FW, Felson DT, Englund M, Wang K, Jarraya M, et al. Factors associated with meniscal extrusion in knees with or at risk for osteoarthritis: the Multicenter Osteoarthritis Study. *Radiol.* 2012;264(2):494–503. <https://doi.org/10.1148/radiol.12110986>.
  40. Englund M, Roemer FW, Hayashi D, Crema MD, Guermazi A. Meniscus pathology, osteoarthritis and the treatment controversy. *Nat Rev Rheumatol.* 2012;8(7):412–9. <https://doi.org/10.1038/nrrheum.2012.69>.
  41. MacLeod TD, Subburaj K, Wu S, Kumar D, Wyatt C, Souza RB. Magnetic resonance analysis of loaded meniscus deformation: a novel technique comparing participants with and without radiographic knee osteoarthritis. *Skeletal Radiol.* 2015;44(1):125–35. <https://doi.org/10.1007/s00256-014-2022-3>.
  42. Patel R, Eltgroth M, Souza R, Zhang CA, Majumdar S, Link TM, et al. Loaded versus unloaded magnetic resonance imaging (MRI) of the knee: effect on meniscus extrusion in healthy volunteers and patients with osteoarthritis. *Eur J Radiol Open.* 2016;3:100–7. <https://doi.org/10.1016/j.ejro.2016.05.002>.
  43. Ishii Y, Ishikawa M, Kurumadani H, Hayashi S, Nakamae A, Nakasa T, et al. Increase in medial meniscal extrusion in the weight-bearing position observed on ultrasonography correlates with lateral thrust in early-stage knee osteoarthritis. *J Orthop Sci.* 2020;25(4):640–6. <https://doi.org/10.1016/j.jos.2019.07.003>.
  44. Ishii Y, Nakashima Y, Ishikawa M, Sunagawa T, Okada K, Takagi K, et al. Dynamic ultrasonography of the medial meniscus during walking in knee osteoarthritis. *Knee.* 2020;27(4):1256–62. <https://doi.org/10.1016/j.knee.2020.05.017>. **(This study used dynamic ultrasonography to measure medial meniscus extrusion in humans during walking.)**
  45. Ishii Y, Deie M, Fujita N, Kurumadani H, Ishikawa M, Nakamae A, et al. Effects of lateral wedge insole application on medial compartment knee osteoarthritis severity evaluated by ultrasound. *Knee.* 2017;24(6):1408–13. <https://doi.org/10.1016/j.knee.2017.09.001>.
  46. Kartus JT, Russell VJ, Salmon LJ, Magnusson LC, Brandsson S, Pehrsson NG, et al. Concomitant partial meniscectomy worsens outcome after arthroscopic anterior cruciate ligament reconstruction. *Acta Orthop Scand.* 2002;73(2):179–85. <https://doi.org/10.1080/000164702753671777>.
  47. Bedi A, Kelly N, Baad M, Fox AJ, Ma Y, Warren RF, et al. Dynamic contact mechanics of radial tears of the lateral meniscus: implications for treatment. *Arthrosc.* 2012;28(3):372–81. <https://doi.org/10.1016/j.arthro.2011.08.287>.
  48. Bansal S, Miller LM, Patel JM, Meadows KD, Eby MR, Saleh KS, et al. Transection of the medial meniscus anterior horn results in cartilage degeneration and meniscus remodeling in a large animal model. *J Orthop Res.* 2020;38(12):2696–708. <https://doi.org/10.1002/jor.24694>. **(This study utilized a large animal model of detachment of the anterior horn of the medial meniscus to characterize degenerative changes to the meniscus and cartilage at multiple scales across a 3-month period.)**
  49. Carter TE, Taylor KA, Spritzer CE, Utturkar GM, Taylor DC, Moorman CT 3rd, et al. In vivo cartilage strain increases following medial meniscal tear and correlates with synovial fluid matrix metalloproteinase activity. *J Biomech.* 2015;48(8):1461–8. <https://doi.org/10.1016/j.jbiomech.2015.02.030>.
  50. Maher SA, Wang H, Koff MF, Belkin N, Potter HG, Rodeo SA. Clinical platform for understanding the relationship between joint contact mechanics and articular cartilage changes after meniscal surgery. *J Orthop Res.* 2017;35(3):600–11. <https://doi.org/10.1002/jor.23365>.
  51. Spang RC III, Nasr MC, Mohamadi A, DeAngelis JP, Nazarian A, Ramappa AJ. Rehabilitation following meniscal repair: a systematic review. *BMJ Open Sport Exerc Med.* 2018;4(1):e000212. <https://doi.org/10.1136/bmjsem-2016-000212>.
  52. McNulty AL, Guilak F. Mechanobiology of the meniscus. *J Biomech.* 2015;48(8):1469–78. <https://doi.org/10.1016/j.jbiomech.2015.02.008>.
  53. Andress BD, Irwin RM, Puranam I, Hoffman BD, McNulty AL. A tale of two loads: modulation of IL-1 induced inflammatory responses of meniscal cells in two models of dynamic physiologic loading. *Front Bioeng Biotechnol.* 2022;10: 837619. <https://doi.org/10.3389/fbioe.2022.837619>. **(This study compared two models of meniscus mechanical stimulation, dynamic compression of tissue explants and cyclic tensile stretch of isolated meniscus cells, to identify conserved responses to mechanical loading. RNA sequencing results from both models showed significant modulation of inflammation-related pathways with mechanical stimulation.)**
  54. Upton ML, Chen J, Guilak F, Setton LA. Differential effects of static and dynamic compression on meniscal cell gene expression. *J Orthop Res.* 2003;21(6):963–9. [https://doi.org/10.1016/S0736-0266\(03\)00063-9](https://doi.org/10.1016/S0736-0266(03)00063-9).
  55. McHenry JA, Zielinska B, Donahue TL. Proteoglycan breakdown of meniscal explants following dynamic compression using a novel bioreactor. *Ann Biomed Eng.* 2006;34(11):1758–66. <https://doi.org/10.1007/s10439-006-9178-5>.
  56. Eifler RL, Blough ER, Dehlin JM, Haut Donahue TL. Oscillatory fluid flow regulates glycosaminoglycan production via an intracellular calcium pathway in meniscal cells. *J Orthop Res.* 2006;24(3):375–84. <https://doi.org/10.1002/jor.20028>.
  57. Deschner J, Wypasek E, Ferretti M, Rath B, Anghelina M, Agarwal S. Regulation of RANKL by biomechanical loading in fibrochondrocytes of meniscus. *J Biomech.* 2006;39(10):1796–803. <https://doi.org/10.1016/j.jbiomech.2005.05.034>.
  58. Ferretti M, Madhavan S, Deschner J, Rath-Deschner B, Wypasek E, Agarwal S. Dynamic biophysical strain modulates proinflammatory gene induction in meniscal fibrochondrocytes. *Am J Physiol Cell Physiol.* 2006;290(6):C1610–5. <https://doi.org/10.1152/ajpcell.00529.2005>.
  59. Madhavan S, Anghelina M, Sjoström D, Dossumbekova A, Guttridge DC, Agarwal S. Biomechanical signals suppress TAK1 activation to inhibit NF-kappaB transcriptional activation in fibrochondrocytes. *J Immunol.* 2007;179(9):6246–54. <https://doi.org/10.4049/jimmunol.179.9.6246>.

60. McNulty AL, Estes BT, Wilusz RE, Weinberg JB, Guilak F. Dynamic loading enhances integrative meniscal repair in the presence of interleukin-1. *Osteoarthr Cartil.* 2010;18(6):830–8. <https://doi.org/10.1016/j.joca.2010.02.009>.
61. Ballyns JJ, Bonassar LJ. Dynamic compressive loading of image-guided tissue engineered meniscal constructs. *J Biomech.* 2011;44(3):509–16. <https://doi.org/10.1016/j.jbiomech.2010.09.017>.
62. Furumatsu T, Kanazawa T, Miyake Y, Kubota S, Takigawa M, Ozaki T. Mechanical stretch increases Smad3-dependent CCN2 expression in inner meniscus cells. *J Orthop Res.* 2012;30(11):1738–45. <https://doi.org/10.1002/jor.22142>.
63. Kanazawa T, Furumatsu T, Hachioji M, Oohashi T, Ninomiya Y, Ozaki T. Mechanical stretch enhances COL2A1 expression on chromatin by inducing SOX9 nuclear translocalization in inner meniscus cells. *J Orthop Res.* 2012;30(3):468–74. <https://doi.org/10.1002/jor.21528>.
64. Puetzer JL, Ballyns JJ, Bonassar LJ. The effect of the duration of mechanical stimulation and post-stimulation culture on the structure and properties of dynamically compressed tissue-engineered menisci. *Tissue Eng Part A.* 2012;18(13–14):1365–75. <https://doi.org/10.1089/ten.TEA.2011.0589>.
65. Favre J, Jolles BM. Gait analysis of patients with knee osteoarthritis highlights a pathological mechanical pathway and provides a basis for therapeutic interventions. *EFORT Open Rev.* 2016;1(10):368–74. <https://doi.org/10.1302/2058-5241.1.000051>.
66. Henriksen M, Graven-Nielsen T, Aaboe J, Andriacchi TP, Bliddal H. Gait changes in patients with knee osteoarthritis are replicated by experimental knee pain. *Arthritis Care Res (Hoboken).* 2010;62(4):501–9. <https://doi.org/10.1002/acr.20033>.
67. Ro DH, Lee J, Lee J, Park JY, Han HS, Lee MC. Effects of knee osteoarthritis on hip and ankle gait mechanics. *Adv Orthop.* 2019;2019:9757369. <https://doi.org/10.1155/2019/9757369>.
68. Cutcliffe HC, Kottamasu PK, McNulty AL, Goode AP, Spritzer CE, DeFrate LE. Mechanical metrics may show improved ability to predict osteoarthritis compared to T1rho mapping. *J Biomech.* 2021;129:110771. <https://doi.org/10.1016/j.jbiomech.2021.110771>.
69. Setton LA, Elliott DM, Mow VC. Altered mechanics of cartilage with osteoarthritis: human osteoarthritis and an experimental model of joint degeneration. *Osteoarthr Cartil.* 1999;7(1):2–14. <https://doi.org/10.1053/joca.1998.0170>.
70. Daszkiewicz K, Łuczkiwicz P. Biomechanics of the medial meniscus in the osteoarthritic knee joint. *PeerJ.* 2021;9:e12509. <https://doi.org/10.7717/peerj.12509>.
71. Seitz AM, Osthaus F, Schwer J, Warnecke D, Faschingbauer M, Sgroi M, et al. Osteoarthritis-related degeneration alters the biomechanical properties of human menisci before the articular cartilage. *Front Bioeng Biotechnol.* 2021;9:659989. <https://doi.org/10.3389/fbioe.2021.659989>.
72. Warnecke D, Balko J, Haas J, Bieger R, Leucht F, Wolf N, et al. Degeneration alters the biomechanical properties and structural composition of lateral human menisci. *Osteoarthr Cartil.* 2020;28(11):1482–91. <https://doi.org/10.1016/j.joca.2020.07.004>.
73. Englund M, Guermazi A, Lohmander SL. The role of the meniscus in knee osteoarthritis: a cause or consequence? *Radiol Clin North Am.* 2009;47(4):703–12. <https://doi.org/10.1016/j.rcl.2009.03.003>.
74. Noble J, Hamblen DL. The pathology of the degenerate meniscus lesion. *J Bone Joint Surg Br.* 1975;57(2):180–6.
75. Sward P, Frobell R, Englund M, Roos H, Struglics A. Cartilage and bone markers and inflammatory cytokines are increased in synovial fluid in the acute phase of knee injury (hemarthrosis)—a cross-sectional analysis. *Osteoarthr Cartil.* 2012;20(11):1302–8. <https://doi.org/10.1016/j.joca.2012.07.021>.
76. Bigoni M, Turati M, Sacerdote P, Gaddi D, Piatti M, Castellnuovo A, et al. Characterization of synovial fluid cytokine profiles in chronic meniscal tear of the knee. *J Orthop Res.* 2017;35(2):340–6. <https://doi.org/10.1002/jor.23272>.
77. Clair AJ, Kingery MT, Anil U, Kenny L, Kirsch T, Strauss EJ. Alterations in synovial fluid biomarker levels in knees with meniscal injury as compared with asymptomatic contralateral knees. *Am J Sports Med.* 2019;47(4):847–56. <https://doi.org/10.1177/0363546519825498>. **(This study assessed synovial fluid biomarkers in patients undergoing arthroscopic meniscectomy, comparing operative and contralateral knees. There were significantly higher levels of IL-6, MIP-1 $\beta$ , MCP-1, and MMP-3 in the operative knee compared to the contralateral knees.)**
78. Ochi M, Uchio Y, Okuda K, Shu N, Yamaguchi H, Sakai Y. Expression of cytokines after meniscal rasping to promote meniscal healing. *Arthrosc.* 2001;17(7):724–31. <https://doi.org/10.1053/jars.2001.23583>.
79. van den Berg WB, Joosten LA, van de Loo FA. TNF alpha and IL-1 beta are separate targets in chronic arthritis. *Clin Exp Rheumatol.* 1999;17(6 Suppl 18):S105–14.
80. McNulty AL, Moutos FT, Weinberg JB, Guilak F. Enhanced integrative repair of the porcine meniscus in vitro by inhibition of interleukin-1 or tumor necrosis factor alpha. *Arthritis Rheum.* 2007;56(9):3033–42. <https://doi.org/10.1002/art.22839>.
81. Wilusz RE, Weinberg JB, Guilak F, McNulty AL. Inhibition of integrative repair of the meniscus following acute exposure to interleukin-1 in vitro. *J Orthop Res.* 2008;26(4):504–12. <https://doi.org/10.1002/jor.20538>.
82. Billingham RC, Dahlberg L, Ionescu M, Reiner A, Bourne R, Rorabeck C, et al. Enhanced cleavage of type II collagen by collagenases in osteoarthritic articular cartilage. *J Clin Invest.* 1997;99(7):1534–45. <https://doi.org/10.1172/JCI119316>.
83. Murphy G, Nagase H. Progress in matrix metalloproteinase research. *Mol Aspects Med.* 2008;29(5):290–308. <https://doi.org/10.1016/j.mam.2008.05.002>.
84. Brophy RH, Rai MF, Zhang Z, Torgomyan A, Sandell LJ. Molecular analysis of age and sex-related gene expression in meniscal tears with and without a concomitant anterior cruciate ligament tear. *J Bone Joint Surg Am.* 2012;94(5):385–93. <https://doi.org/10.2106/JBJS.K.00919>.
85. Killian ML, Zielinska B, Gupta T, Haut Donahue TL. In vitro inhibition of compression-induced catabolic gene expression in meniscal explants following treatment with IL-1 receptor antagonist. *J Orthop Sci.* 2011;16(2):212–20. <https://doi.org/10.1007/s00776-011-0026-6>.
86. Blain EJ. Mechanical regulation of matrix metalloproteinases. *Front Biosci.* 2007;12:507–27. <https://doi.org/10.2741/2078>.
87. Cook AE, Stoker AM, Leary EV, Pfeiffer FM, Cook JL. Metabolic responses of meniscal explants to injury and inflammation ex vivo. *J Orthop Res.* 2018;36(10):2657–63. <https://doi.org/10.1002/jor.24045>.
88. McNulty AL, Rothfus NE, Leddy HA, Guilak F. Synovial fluid concentrations and relative potency of interleukin-1 alpha and beta in cartilage and meniscus degradation. *J Orthop Res.* 2013;31(7):1039–45. <https://doi.org/10.1002/jor.22334>.

89. Liu B, Goode AP, Carter TE, Utturkar GM, Huebner JL, Taylor DC, et al. Matrix metalloproteinase activity and prostaglandin E2 are elevated in the synovial fluid of meniscus tear patients. *Connect Tissue Res.* 2017;58(3–4):305–16. <https://doi.org/10.1080/03008207.2016.1256391>.
90. Sokolove J, Lepus CM. Role of inflammation in the pathogenesis of osteoarthritis: latest findings and interpretations. *Ther Adv Musculoskelet Dis.* 2013;5(2):77–94. <https://doi.org/10.1177/1759720X12467868>.
91. Martel-Pelletier J, Pelletier JP, Fahmi H. Cyclooxygenase-2 and prostaglandins in articular tissues. *Semin Arthritis Rheum.* 2003;33(3):155–67. [https://doi.org/10.1016/s0049-0172\(03\)00134-3](https://doi.org/10.1016/s0049-0172(03)00134-3).
92. • Turati M, Maggioni D, Zanchi N, Gandolla M, Gorla M, Sacerdote P, et al. Characterization of synovial cytokine patterns in bucket-handle and posterior horn meniscal tears. *Mediators Inflamm.* 2020;2020:5071934. <https://doi.org/10.1155/2020/5071934>. (This study assessed the levels of pro-inflammatory and anti-inflammatory cytokines in the synovial fluid of meniscus tear patients. They found that TNF- $\alpha$  levels were significantly higher in patients with bucket handle tears compared to posterior horn tears, while IL-1 $\beta$  was significantly higher in patients with posterior horn tears compared to those with bucket handle tears.)
93. Brophy RH, Sandell LJ, Rai MF. Traumatic and degenerative meniscus tears have different gene expression signatures. *Am J Sports Med.* 2017;45(1):114–20. <https://doi.org/10.1177/0363546516664889>.
94. Ogura T, Suzuki M, Sakuma Y, Yamauchi K, Orita S, Miyagi M, et al. Differences in levels of inflammatory mediators in meniscal and synovial tissue of patients with meniscal lesions. *J Exp Orthop.* 2016;3(1):7. <https://doi.org/10.1186/s40634-016-0041-9>.
95. Labarre C, Kim SH, Pujol N. Incidence and type of meniscal tears in multiligament injured knees. *Knee Surg Sports Traumatol Arthrosc.* 2022. <https://doi.org/10.1007/s00167-022-07064-6>.
96. Ding J, Niu X, Su Y, Li X. Expression of synovial fluid biomarkers in patients with knee osteoarthritis and meniscus injury. *Exp Ther Med.* 2017;14(2):1609–13. <https://doi.org/10.3892/etm.2017.4636>.
97. Riera KM, Rothfus NE, Wilusz RE, Weinberg JB, Guilak F, McNulty AL. Interleukin-1, tumor necrosis factor- $\alpha$ , and transforming growth factor- $\beta$  1 and integrative meniscal repair: influences on meniscal cell proliferation and migration. *Arthritis Res Ther.* 2011;13(6):R187. <https://doi.org/10.1186/ar3515>.
98. Mull C, Wohlmuth P, Krause M, Alm L, Kling H, Schilling AF, et al. Hepatocyte growth factor and matrix metalloproteinase 2 levels in synovial fluid of the knee joint are correlated with clinical outcome of meniscal repair. *Knee.* 2020;27(4):1143–50. <https://doi.org/10.1016/j.knee.2020.05.001>.
99. Chevalier X, Goupille P, Beaulieu AD, Burch FX, Bensen WG, Conrozier T, et al. Intraarticular injection of anakinra in osteoarthritis of the knee: a multicenter, randomized, double-blind, placebo-controlled study. *Arthritis Rheum.* 2009;61(3):344–52. <https://doi.org/10.1002/art.24096>.
100. Behrendt P, Hafelein K, Preusse-Prange A, Bayer A, Seekamp A, Kurz B. IL-10 ameliorates TNF- $\alpha$  induced meniscus degeneration in mature meniscal tissue in vitro. *BMC Musculoskelet Disord.* 2017;18(1):197. <https://doi.org/10.1186/s12891-017-1561-x>.
101. McNulty AL, Miller MR, O'Connor SK, Guilak F. The effects of adipokines on cartilage and meniscus catabolism. *Connect Tissue Res.* 2011;52(6):523–33. <https://doi.org/10.3109/03008207.2011.597902>.
102. Shen C, Yan J, Erkokoc OF, Zheng XF, Chen XD. Nitric oxide inhibits autophagy via suppression of JNK in meniscal cells. *Rheumatol (Oxford).* 2014;53(6):1022–33. <https://doi.org/10.1093/rheumatology/ket471>.
103. Hennerbichler A, Moutos FT, Hennerbichler D, Weinberg JB, Guilak F. Interleukin-1 and tumor necrosis factor  $\alpha$  inhibit repair of the porcine meniscus in vitro. *Osteoarthr Cartil.* 2007;15(9):1053–60. <https://doi.org/10.1016/j.joca.2007.03.003>.
104. McNulty AL, Weinberg JB, Guilak F. Inhibition of matrix metalloproteinases enhances in vitro repair of the meniscus. *Clin Orthop Relat Res.* 2009;467(6):1557–67. <https://doi.org/10.1007/s11999-008-0596-6>.
105. • Kim-Wang SY, Holt AG, McGowan AM, Danyluk ST, Goode AP, Lau BC, et al. Immune cell profiles in synovial fluid after anterior cruciate ligament and meniscus injuries. *Arthritis Res Ther.* 2021;23(1):280. <https://doi.org/10.1186/s13075-021-02661-1>. (This study characterized immune cell profiles in the synovial fluid of ACL- and meniscus-injured knees. Total viable and CD3+ T cells were significantly elevated in the injured knees as compared to contralateral control knees.)
106. Lurati A, Laria A, Gatti A, Brando B, Scarpellini M. Different T cells' distribution and activation degree of Th17 CD4+ cells in peripheral blood in patients with osteoarthritis, rheumatoid arthritis, and healthy donors: preliminary results of the MAGENTA CLICAO study. *Open Access Rheumatol.* 2015;7:63–8. <https://doi.org/10.2147/OARRR.S81905>.
107. Rosshirt N, Hagmann S, Tripel E, Gotterbarm T, Kirsch J, Zeifang F, et al. A predominant Th1 polarization is present in synovial fluid of end-stage osteoarthritic knee joints: analysis of peripheral blood, synovial fluid and synovial membrane. *Clin Exp Immunol.* 2019;195(3):395–406. <https://doi.org/10.1111/cei.13230>.
108. Koenders MI, Joosten LA, van den Berg WB. Potential new targets in arthritis therapy: interleukin (IL)-17 and its relation to tumour necrosis factor and IL-1 in experimental arthritis. *Ann Rheum Dis.* 2006;65 Suppl 3:iii29–33. <https://doi.org/10.1136/ard.2006.058529>.
109. Wynn TA, Chawla A, Pollard JW. Macrophage biology in development, homeostasis and disease. *Nat.* 2013;496(7446):445–55. <https://doi.org/10.1038/nature12034>.
110. Kraus VB, McDaniel G, Huebner JL, Stabler TV, Pieper CF, Shipes SW, et al. Direct in vivo evidence of activated macrophages in human osteoarthritis. *Osteoarthr Cartil.* 2016;24(9):1613–21. <https://doi.org/10.1016/j.joca.2016.04.010>.
111. Griffin TM, Scanzello CR. Innate inflammation and synovial macrophages in osteoarthritis pathophysiology. *Clin Exp Rheumatol.* 2019;37 Suppl 120(5):57–63.
112. Woodell-May JE, Sommerfeld SD. Role of inflammation and the immune system in the progression of osteoarthritis. *J Orthop Res.* 2020;38(2):253–7. <https://doi.org/10.1002/jor.24457>.
113. Bondeson J, Blom AB, Wainwright S, Hughes C, Caterson B, van den Berg WB. The role of synovial macrophages and macrophage-produced mediators in driving inflammatory and destructive responses in osteoarthritis. *Arthritis Rheum.* 2010;62(3):647–57. <https://doi.org/10.1002/art.27290>.
114. Wu CL, McNeill J, Goon K, Little D, Kimmerling K, Huebner J, et al. Conditional macrophage depletion increases inflammation and does not inhibit the development of osteoarthritis in obese macrophage fas-induced apoptosis-transgenic mice. *Arthritis*

- Rheumatol. 2017;69(9):1772–83. <https://doi.org/10.1002/art.40161>.
115. Bailey KN, Furman BD, Zeitlin J, Kimmerling KA, Wu CL, Guilak F, et al. Intra-articular depletion of macrophages increases acute synovitis and alters macrophage polarity in the injured mouse knee. *Osteoarthr Cartil.* 2020;28(5):626–38. <https://doi.org/10.1016/j.joca.2020.01.015>.
116. Nishida Y, Hashimoto Y, Orita K, Nishino K, Kinoshita T, Nakamura H. Intra-articular injection of stromal cell-derived factor 1alpha promotes meniscal healing via macrophage and mesenchymal stem cell accumulation in a rat meniscal defect model. *Int J Mol Sci.* 2020;21(15):5454. <https://doi.org/10.3390/ijms21155454>.
117. Rowe MA, Harper LR, McNulty MA, Lau AG, Carlson CS, Leng L, et al. Reduced osteoarthritis severity in aged mice with deletion of macrophage migration inhibitory factor. *Arthritis Rheumatol.* 2017;69(2):352–61. <https://doi.org/10.1002/art.39844>.

**Publisher's Note** Springer Nature remains neutral with regard to jurisdictional claims in published maps and institutional affiliations.

Springer Nature or its licensor (e.g. a society or other partner) holds exclusive rights to this article under a publishing agreement with the author(s) or other rightsholder(s); author self-archiving of the accepted manuscript version of this article is solely governed by the terms of such publishing agreement and applicable law.