

Surgical management options for long-bone metastasis

Catalin Cirstoiu^{1,2}, Bogdan Cretu^{1,2}, Sergiu Iordache^{1,2}, Mihnea Popa^{1,2}, Bogdan Serban^{1,2} and Adrian Cursaru^{1,2}

¹Orthopedics and Traumatology Department, Carol Davila University of Medicine and Pharmacy, Bucharest, Romania

²Orthopedics and Traumatology Department, University Emergency Hospital Bucharest, Bucharest, Romania

Correspondence should be addressed to B Cretu
Email
jfrbogdan@yahoo.com

- Bone metastases are difficult to treat surgically, necessitating a multidisciplinary approach that must be applied to each patient depending on the specifics of their case.
- The main indications for surgical treatment are a lack of response to chemotherapy, radiation therapy, hormone therapy, immunotherapy, and bisphosphonates which is defined by persistent pain or tumor progression; the risk of imminent pathological bone fracture; and surgical treatment for single bone metastases.
- An important aspect of choosing the right treatment for these patients is accurately estimating life expectancy. Improved chemotherapy, postoperative radiation therapy, and sustainable reconstructive modalities will increase the patient's life expectancy.
- The surgeon should select the best surgical strategy based on the primary tumor and its characteristics, the presence of single or multiple metastases, age, anatomical location, and the functional resources of the patient.
- Preventive osteosynthesis, osteosynthesis to stabilize a fracture, resections, and reconstructions are the main surgical options for bone metastases.
- Resection and reconstruction with a modular prosthesis remain the generally approved surgical option to restore functionality, increase the quality of life, and increase life expectancy.
- Preoperative embolization is necessary, especially in the case of metastases of renal or thyroid origin. This procedure is extremely important to avoid complications, with a major impact on survival rates.

Keywords

- ▶ bone metastasis
- ▶ impending fractures
- ▶ resection reconstruction

EFORT Open Reviews
(2022) 7, 206–213

Introduction

The most common malignant bone tumors are bone metastases, which are caused by visceral tumors and primary hematopoietic neof ormations. With the evolution of oncological treatments, which have led to increased survival of cancer patients, the incidence of bone metastases has increased. Because of the discomfort and possibility of pathological bone fractures, quality of life is significantly impaired by the presence of bone metastases. The most common primary malignancies that cause bone metastases are in the breast, prostate, lung, kidney, and thyroid. The evolution of a bone metastasis depends on the affected bone type and its location. The most common sites of bone metastases are the spine, proximal femur, pelvis, ribs, and proximal humerus.

Patients with tumor bone lesions are divided into two categories: patients with a previously diagnosed tumor

and patients with no known history of neoplasms who are on the first presentation. In the face of a suspicious bone lesion, a primary tumor should always be excluded, especially in the case of a patient without neoplastic history. The next step in the diagnosis and treatment process is staging, localization of the primary lesion, and general investigations. All decisions regarding staging and diagnosis should be discussed in a multidisciplinary team before any treatment is applied.

A biopsy will be required to determine the primary tumor in patients who have no known neoplasm but have suspected bone metastasis. It is necessary to perform a complete examination before the biopsy as it may be a primary tumor and the biopsy will have to be placed correctly; another secondary determination may be more accessible for diagnosis; preoperative embolization may

be necessary to avoid massive bleeding; the diagnosis can sometimes be made with the help of laboratory tests, as in the case of myeloma; several pre-biopsy elements can increase the accuracy of the extemporaneous examination; and detailed imaging examinations may be important to the pathologist in the final diagnosis (1).

A separate category is patients who present in the emergency room with a pathological bone fracture. Most pathological bone fractures are secondary to metastatic disease, but benign bone lesions, metabolic diseases, or primary malignant bone tumors should not be dismissed. For the vast majority of patients, a pathological bone fracture will lead to the diagnosis of neoplastic disease. The timing of bone metastases is variable; they can occur many years after the diagnosis of a primary neoplasm or at the same presentation.

The treatment of a metastatic bone lesion has multiple goals that must be achieved, such as reducing pain, restoring functionality, or maintaining functionality without the need for further surgery. Radiotherapy is the most commonly used treatment for bone metastases, but surgical treatment for preventive purposes in the pre-fracture stages, or even for curative purposes in the case of solitary metastases, is an important component of treatment. The indication for surgical treatment of a bone metastasis will always take into account the patient's life expectancy, especially in the short and medium term. When determining whether or not a bone metastasis should be treated surgically, the following factors must be established with certainty: the origin of the neoplasm, whether the metastatic disease is restricted to the bone, the number of bone metastases, and the availability of postoperative chemotherapy and radiotherapy options. At the end of this evaluation, the best therapeutic decision will be made in a multidisciplinary commission.

As a result of the low life expectancy of patients with bone metastatic disease, management of these patients is difficult. The vast majority of patients who suffer from pathological bone fractures as a result of bone metastasis have a life expectancy of less than 6 months (2, 3, 4, 5).

The main challenge of musculoskeletal oncological surgery is to make the best therapeutic decision for a frail patient with multiple risks. Patients with low life expectancy should be identified and should not undergo major resection and reconstruction. In addition, sequential surgical treatments, which may result from insufficient osteosynthesis, should be avoided.

Indications for surgical treatment

Following a multidisciplinary preoperative evaluation, candidates for surgical treatment can be identified and optimal approaches established. The main objective in the case of bone metastases is to restore an optimal functional

status. Palliative treatment is appropriate when we have a generalized metastatic disease, surgically unapproachable metastases, metastases with extensive locoregional extension, or patients with a poor prognosis (Fig. 1). Adjuvant treatment with chemotherapy, low-dose radiation therapy, and palliative surgery are solutions for patients with a fair prognosis. Chemotherapy, high-dose radiation therapy, and surgery, which includes extensive resections and reconstructions, can all be used to improve the long-term survival of patients with a favorable prognosis.

Depending on primary cancer and its characteristics, the number of metastases present and their anatomical location, life expectancy, patient expectations, and activity level, the surgeon will be able to choose the optimal treatment method (Tables 1 and 2).

Preoperative multidisciplinary evaluation is essential in establishing candidates for surgical treatment. The treatment of patients should be closely monitored, and the best time to interrupt them to perform surgery should be determined as soon as possible after diagnosis. Tyrosine kinase inhibitors should be stopped approximately 7 days prior to surgery due to the risk of bleeding, and treatment should be resumed once the wound has healed. Monoclonal antibodies should be used with caution during the perioperative period due to the potential for infectious complications.

Single bone metastases in the pre-fracture stage, or even with an associated fracture, should be treated with extensive resections and reconstructions to considerably improve long-term life expectancy.

Regarding multiple metastatic disease in which a bone metastasis is in the pre-fracture stage, prophylactic fixation has proven to be cost-effective with the optimal restoration of functionality compared to the treatment of a fracture. In areas where bone destruction is important, increasing osteosynthesis resistance with acrylic cement may be a solution. If there is a risk that the fixation will fail due to advanced local destruction, resection and reconstruction may avoid subjecting the

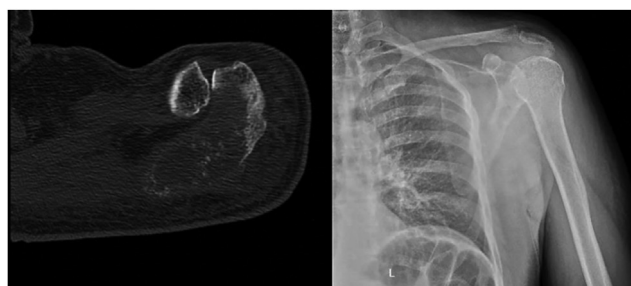

Figure 1

Extensive locoregional acromial metastasis in a 61-year-old female secondary to breast adenocarcinoma, the patient presenting with multiple metastasis at diagnosis.

Table 1 Surgical treatment of lower limb metastatic disease of the bone.

Anatomical location	Single metastasis (fractured or not)	Multiple metastases		Any type of metastasis
		Impending fracture	Fractured	
Pelvic Periacetabular				Non-surgical treatment Harrington procedure used for periacetabular impending fractures or periacetabular fractures
Proximal femur	Resection–reconstruction with modular prosthesis	Resection–reconstruction (modular prosthesis vs arthroplasty) Preventive osteosynthesis ± PMMA	Resection–reconstruction (modular prosthesis vs arthroplasty) Osteosynthesis ± PMMA	
Femoral shaft	Resection–reconstruction with modular prosthesis	Resection–reconstruction (modular prosthesis) Preventive osteosynthesis ± PMMA	Resection–reconstruction (modular prosthesis) Osteosynthesis ± PMMA	
Distal femur	Resection–reconstruction with modular prosthesis	Preventive osteosynthesis ± PMMA	Osteosynthesis ± PMMA	
Proximal tibia	Resection arthrodesis Resection–reconstruction with modular prosthesis	Resection arthrodesis Preventive osteosynthesis ± PMMA	Resection arthrodesis Osteosynthesis ± PMMA	
Tibial shaft	Resection arthrodesis Resection–reconstruction with modular prosthesis	Resection arthrodesis Preventive osteosynthesis ± PMMA	Resection arthrodesis Osteosynthesis ± PMMA	
Distal calf and foot				Non-surgical treatment

patient to secondary intervention. In the case of a bone metastasis associated with a pathological bone fracture, osteosynthesis or reconstruction should be considered. For patients with a high level of activity, a definitive treatment, such as segmental resection or arthroplasty, should be chosen.

Complications of surgical treatment may vary depending on the location of the tumor, the type of tumor, and the surgical technique used. Pseudarthrosis, peri-implant fractures, and implant degradation are responsible for 6–15% of post-oncological revisions for bone metastases (6). The complications that can occur are major and represent a challenge for surgeons. Infections and wound complications occur more frequently due to the immunocompromised status of patients.

Treatment of complete and/or impending fractures and postoperative radiation

A fracture that occurs in a modified bone is defined as a pathological bone fracture. These can occur secondary to

trauma or in normal activities. A patient with a pathological bone fracture will follow the standard preoperative protocol for staging and diagnosing the primary tumor. They may have a history of a known neoplasm, which will raise suspicions about the origin of the fracture, or no known history, but tumor tissue from the fracture site will be sent to the pathology laboratory in both cases.

The primary goal of fixing a pathological bone fracture with radiotherapy is to provide sufficient stabilization of the focus in order to improve the patient’s quality of life while avoiding the need for possible secondary interventions. Postoperative radiotherapy is necessary for all patients, except those with a very low life expectancy or if the region has already been irradiated. Radiation therapy begins immediately after surgery, and the radiated area should cover the entire implant; its purpose is to reduce pain, slow progression, or treat any remaining tumor tissue after surgery.

The treatment of a fracture on a bone metastasis varies depending on the location. Centromedullary nails, cephalomedullary nails, hemiarthroplasty, or total arthroplasties with modular prostheses are the main

Table 2 Surgical treatment of upper limb metastatic disease of the bone.

Anatomical location	Single metastasis (fractured or not)	Multiple metastases		All types of metastases
		Impending fracture	Fractured	
Scapula/clavicle Proximal humerus				Non-surgical treatment
Humeral shaft	Resection–reconstruction with modular prosthesis	Resection–reconstruction (modular prosthesis versus arthroplasty) Preventive osteosynthesis ± PMMA	Resection–reconstruction (modular prosthesis versus arthroplasty) Osteosynthesis ± PMMA	
Distal humerus	Resection–reconstruction with modular prosthesis	Preventive osteosynthesis ± PMMA	Osteosynthesis ± PMMA	
Forearm	Resection–reconstruction ± PMMA Reconstruction if instability is present	Preventive osteosynthesis ± PMMA	Osteosynthesis ± PMMA	
Distal forearm and arm				Non-surgical treatment

options (7) (Figs 2 and 3). The correct choice will be made by respecting some basic principles:

1. Is it a unique metastasis?
2. What is the primary tumor?
3. What are the failure rates specific to an implant used in a particular region?
4. What is the functional outcome?

Regarding impending fractures, the management and surgical treatment modalities are the same as for constituted fractures, with the major difference between the two being the indication. There are several elements that predict the risk of a fracture: the presence of significant pain, the destruction of more than 50% of the cortical bone, the Harington criteria, and the Mirel criteria (8, 9). Prophylactic fixation is preferred due to rapid postoperative recovery, low morbidity, and short operating times. The main goal regardless of the stage or technique used is to provide the patient with an implant that allows immediate mobilization with a full load and 'protects' the whole bone in the context of metastatic disease and is optimized in the context of the patient's prognosis.

Complications and osteosynthesis failure after pathological fracture treatment

Modified local biology secondary to bone metastasis decreases the ability of the bone to heal. In the case of osteosynthesis, the use of materials that fail to take over the biomechanical forces of the fracture while substituting the bone defect will lead to degradation of the assembly or peri-implant fractures (Fig. 4). The use of adjuvant chemotherapy and radiotherapy for osteolytic defects secondary to metastasis will certainly lead to complications.

Failure of prosthetic fixation may result when tumor resection has been insufficient, prosthetic fixation is deficient, or prosthetic fixation on the entire length of the bone fails. Cemented components come with the

advantage of immediate fixation. Another advantage is that it does not rely on local biology in terms of prosthetic integration, which allows for quicker return to physical activity.

There are two major errors that an orthopedic surgeon can make in the management of long bone metastasis. Type 1 error is the use of load sharing implants instead of load bearing which will lead to failure of fixation especially for metastatic fractures around the hip. Type 2 error is to use intramedullary nails for solitary lesions wrongly assuming the cause of the pathological bone (10).

Pathological bone fractures occur within the setting of major biomechanical instability, associating large bone defects with low regenerative potential. The fixation methods required for the correct treatment of such lesions should be above those used in the case of a simple fracture in terms of biomechanical strength, and their mechanical load should outlast the patient's life expectancy.

Preoperative embolization

Musculoskeletal oncological surgery can have important complications, such as massive intraoperative bleeding, which can lead to life-threatening events, high transfusion rates during surgery, a substantial increase in operative time, increased rates of perioperative complications, and potential wound complications. Preoperative embolization is often required for bone metastases secondary to renal or thyroid carcinoma due to significant tumor vascularization through the formation of new vessels.

Frequently, we may find ourselves confronted with a unique, operable bone metastasis that will require radical resection followed by reconstruction of the area (Fig. 5). Applying radical resection to a massive tumor formation with important peritumoral vascularization risks unnecessarily prolonging the operating time with heavy bleeding, or even endangering the patient's life. Preoperative angiography, especially in the case of metastasis of renal or thyroid origin, can highlight an important vascularization while performing embolization of the main vascular sources (11).

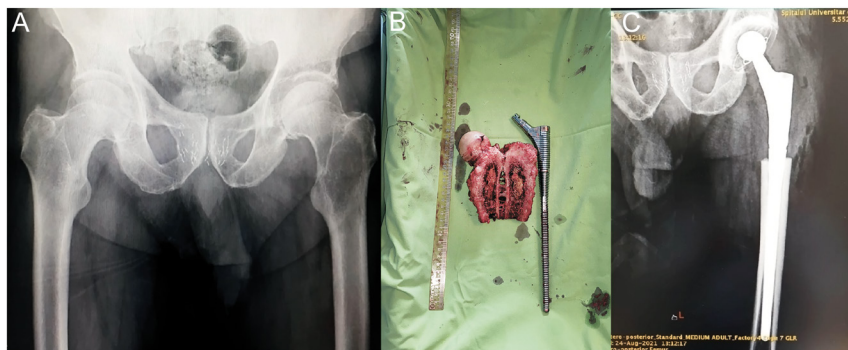

Figure 2

(A) Solitary proximal left femur metastasis with an impending fracture in a 74-year-old male secondary to renal carcinoma. (B) Intraoperative image secondary to resection and measurements for the final prosthesis. (C) Postoperative image of the resection reconstruction with a modular tapered, fluted stem.

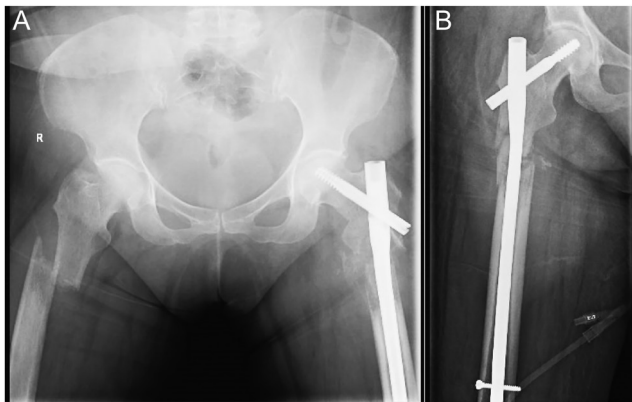


Figure 3
 (A) Preoperative anterior-posterior image of the pelvis of a 68-year-old woman with bilateral subtrochanteric pathological fractures secondary to a cervical neoplasm, recently treated on the left side with a cephalomedullary nail. (B) Postoperative image of the right femur after fracture fixation with a long cephalomedullary nail.

Resection reconstruction with endoprosthesis

From a functional standpoint, such as the ability to resume mobility immediately after surgery and the overall quality of life, resections performed in conjunction with reconstructions are the most effective technique available. This technique can especially be used not only in the case of a single metastasis in order to increase life expectancy but also in multiple metastatic disease to increase the quality of life by avoiding secondary interventions that may occur following the degradation of osteosynthesis.

The most common reconstruction of a bone region after tumor resection is with modular prosthetic systems (Fig. 6). These can be used for the proximal humerus, distal femur, or proximal tibia, along with adjacent joints. Modularity allows the reconstruction of the entire bone segment, such as the humerus or femur. The reconstructed segment may include one or more joints or maybe intercalated, such as a femoral diaphyseal segment. A set of standards must be observed for optimal postoperative

results: exact preoperative planning, accurate resection edges, accurate restoration of limb length, good fixing so that the loading is early and total, restoration of muscle insertions to achieve adequate postoperative mobility.

The main contraindications in the case of resection–reconstruction for bone metastases are damage to the main vascular or nerve bundle and massive extension of the tumor into the soft parts that will not allow the prosthesis to be covered. Relative contraindications for resection and reconstruction in bone metastases could be the poor response to chemotherapy or radiation therapy.

In particular, secondary bone lesions located in the femoral neck should be addressed by arthroplasty (12, 13). The cephalomedullary rods used in this case have high failure rates due to the high biomechanical stress at the level of the femoral neck combined with a lesion that progresses and does not heal. Lesions in the femoral neck can be treated using a long prosthetic stem that will overcome any remaining lesions after the resection of the neck. Long cemented stems should be used with caution in these cases due to potential intraoperative pulmonary complications (14).

The oncological results after surgery are difficult to determine given the large number of variables involved. The primary site, the characteristics of the underlying disease, the progressive potential of the tumor, the characteristics of the patient, the location of the metastatic disease and the number of metastases, and existing oncological, radiotherapeutic, and surgical treatment must be determined exactly. Even in the case of a patient with a short life expectancy, the functional outcome following reconstruction resection will be significantly improved, with improvement occurring in at least 50% of patients (15).

Resection arthrodesis with intramedullary nails and acrylic bone cement

This reconstructive surgical method after resection is suitable in the case of tumor formation adjacent to a joint,

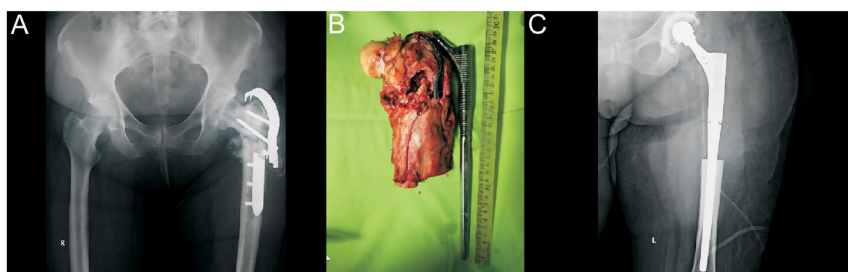


Figure 4
 (A) A 60-year-old patient previously known to have a subtrochanteric fracture on the pathological bone secondary to breast carcinoma initially treated with a cephalomedullary nail that failed, later replaced with this plate that also failed. (B) Intraoperative resected segment and prosthetic measurements. (C) Postoperative X-ray after resection and reconstruction with a long modular fluted stem.

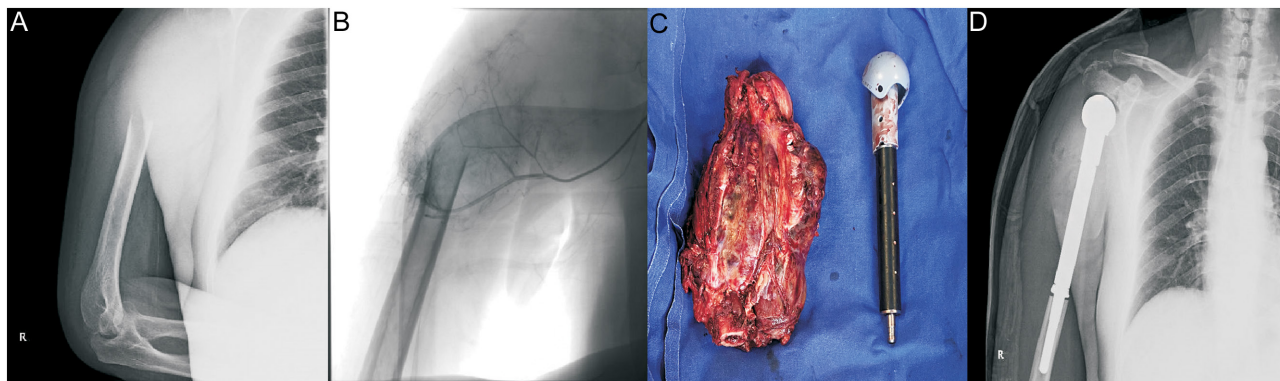


Figure 5

(A) Preoperative X-ray of a 56-year-old male diagnosed with a solitary proximal humerus metastasis secondary to renal carcinoma. (B) Preoperative angiography and embolization of the tumor were performed prior to resection to limit intraoperative blood loss. (C) Intraoperative image of the tumor resection and intraoperative measurements. (D) Postoperative image of the modular prosthesis used after tumor resection.

especially in the case of those located in the knee region. Described by Professor Mario Campanacci, resection-knee arthrodesis has been recommended as a debulking procedure when metastatic disease is present in young patients and when other reconstructive modalities are unavailable. In the case of a distal femur or proximal tibia metastasis that is suitable for resection and reconstruction, this technique can provide a stable knee with a durable fit. The advantage of using this technique in the case of a distal femoral metastasis or proximal tibia is that it can be used until the oncological prognosis is optimal and a definitive reconstruction can be performed.

The disadvantages are a complete loss of knee mobility, decreased quality of life, and risks associated with the assembly, such as its failure, peri-implant fracture, or associated infection.

Periacetabular metastasis

Acetabular fractures secondary to metastasis are uncommon but have important implications for the hip function and represent a difficult surgical challenge. Surgical technique with promising results described by Harrington and later modified, consisting of reconstruction of the ilium, using threaded pins inserted retrograde through the acetabular roof and into the iliac wing represents an important choice of treatment. The pins are cemented together with

an acetabular support ring in which a polyethylene base is cemented. The results of these techniques are validated by studies that demonstrate effectiveness in terms of quickly restoring the mobility of the patient, pain relief, and in terms of cost-effectiveness (16, 17).

Discussion

Each neoplasm has its own characteristics in terms of life expectancy, the healing potential of a fracture, local and systemic progression, and sensitivity to various treatments (18). Following the appreciation of these characteristics within the multidisciplinary team, valid decisions can be made regarding potential treatments. To choose a treatment, we need to know the average life expectancy for each neoplasm with bone metastases: 48 months for thyroid neoplasm, 40 months for prostate, 24 months for breast, 6 months to 4–5 years for renal neoplasm depending on the type, and 6–7 months for lung cancer (19).

Following the advancement of oncological therapies, the increase in life expectancy has coincided with an increase in the incidence of bone metastases, especially in the case of renal carcinoma, where bone metastases are increasingly common and resistant to radiation therapy. Resection followed by endoprosthesis reconstruction

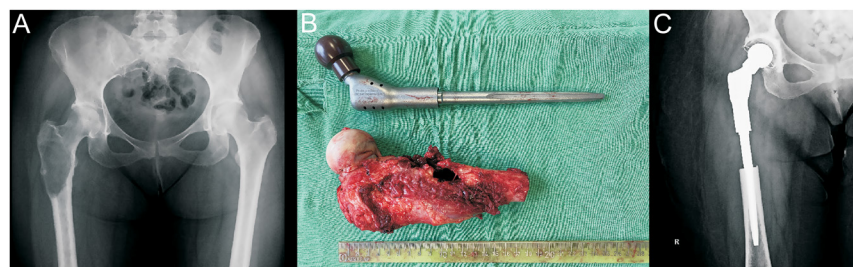


Figure 6

(A) Solitary metastasis of the proximal femur secondary to breast carcinoma in a 46-year-old female. (B) Intraoperative image of the tumor resection. (C) Postoperative x-ray of the modular prosthesis used for reconstruction of the proximal femur.

of metastases secondary to renal cell carcinoma should be considered a standard procedure with the lowest complication rate (20). Unique metastases in the context of increased life expectancy due to new lines of cancer treatment must be treated by resection and reconstruction, especially in the case of primary tumors for which life expectancy is high.

The use of preventive osteosynthesis is required in the case of bone metastases from metastatic disease that has spread to the diaphyseal level in order to avoid fractures. Centromedullary osteosynthesis is the main method of fixing such a lesion, and implant failure must be minimized by choosing the correct implant, observing the surgical technique, and correctly estimating the patient's life expectancy (21). Pathological bone fractures are often the main symptom of metastatic disease with a known or unknown primary neoplasm. The purpose of surgical treatment is to restore preoperative functionality and provide lasting stability so that secondary interventions are avoided. The method of surgical treatment should be chosen depending on the anatomical location and local evolution. Fixation using osteosynthesis methods, such as plates and screws or centromedullary rods, can be increased by acrylic cement. Acrylic cement will increase structural stability and increase the biomechanical rigidity of the implant (22). In some cases, due to the localization or advanced local evolution, reconstructive methods should be used.

The benefit of restoring functionality and increasing life expectancy with the cost-effectiveness of this type of surgical approach of bone metastases should be underlined (23).

Accurate understanding of the life expectancy of a patient with metastatic disease can help avoid mistakes in choosing the type of treatment. Patients with a high life expectancy may benefit from reconstructive resection, taking into account that some of them will survive longer than the reconstruction (24). Life expectancy will be estimated within the multidisciplinary treatment team, followed by a decision on the individualized type of intervention (25).

Conclusions

Bone metastasis management is a difficult task that necessitates the use of a multidisciplinary approach. Palletia is frequently the only option for patients who have been carefully monitored and diagnosed early. A combination of chemotherapy, radiotherapy, and surgery can significantly increase life expectancy in these patients. Surgical treatment can be used to maintain the functionality of a region, but it can also be used to cure a

single metastasis if the metastasis is located in a specific location.

The best treatment option for a patient with metastatic bone disease will be determined only after a thorough preoperative evaluation has been completed and the exact origin of the neoplasm has been determined. As soon as the surgical indication has been established, the various specific reconstructive methods for the resected area will be discussed in greater detail. Patient-centered methods that not only extend patient life expectancy but also restore functionality will be selected in order to avoid the need for additional surgeries as a result of implant degradation.

Knowledge of the type of neoplasm responsible for metastatic disease is essential not only for determining oncological treatment options but also for determining the feasibility of a preoperative angiographic evaluation for embolization in order to avoid intraoperative complications that could be fatal.

ICMJE Conflict of Interest Statement

The authors declare that there is no conflict of interest that could be perceived as prejudicing the impartiality of the research reported.

Funding Statement

This work did not receive any specific grant from any funding agency in the public, commercial, or not-for-profit sector.

References

1. Simon MA & Finn HA. Diagnostic strategy for bone and soft-tissue tumors. *Journal of Bone and Joint Surgery: American Volume* 1993 **75** 622–631. (<https://doi.org/10.2106/00004623-199304000-00019>)
2. Dijstra S, Wiggers T, van Geel BN & Boxma H. Impending and actual pathological fractures in patients with bone metastasis of long bones. A retrospective study of 233 surgically treated fractures. *European Journal of Surgery* 1994 **160** 535–542.
3. Hansen BH, Keller J, Laitinen M, Berg P, Skjeldal S, Trovik C, Nilsson J, Walloe A, Kalén A & Wedin R. The Scandinavian Sarcoma Group Skeletal Metastasis Registry. Survival after surgery for bone metastasis in the pelvis and extremities. *Acta Orthopaedica Scandinavica: Supplementum* 2004 **75** 11–15. (<https://doi.org/10.1080/0016470410001708270>)
4. Wedin R, Bauer HC & Rutqvist LE. Surgical treatment for skeletal breast cancer metastasis: a population-based study of 641 patients. *Cancer* 2001 **92** 257–262. ([https://doi.org/10.1002/1097-0142\(20010715\)92:2<257::aid-cncr1317>3.0.co;2-r](https://doi.org/10.1002/1097-0142(20010715)92:2<257::aid-cncr1317>3.0.co;2-r))
5. Yazawa Y, Frassica FJ, Chao EY, Pritchard DJ, Sim FH & Shives TC. Metastatic bone disease. A study of the surgical treatment of 166 pathologic humeral and femoral fractures. *Clinical Orthopaedics and Related Research* 1990 **251** 213–219. (<https://doi.org/10.1097/00003086-199002000-00036>)
6. Weiss RJ, Tullberg E, Forsberg JA, Bauer HC & Wedin R. Skeletal metastasis in 301 breast cancer patients: survival and complications after surgery. *Breast* 2014 **23** 286–290. (<https://doi.org/10.1016/j.breast.2014.02.012>)

- 7. Quinn RH, Randall RL, Benevenia J, Berven SH & Raskin KA.** Contemporary management of metastatic bone disease: tips and tools of the trade for general practitioners. *Journal of Bone and Joint Surgery: American Volume* 2013 **95** 1887–1895. (<https://doi.org/10.2106/00004623-201310160-00011>)
- 8. Evans AR, Bottros J, Grant W, Chen BY & Damron TA.** Mirels' rating for humerus lesions is both reproducible and valid. *Clinical Orthopaedics and Related Research* 2008 **466** 1279–1284. (<https://doi.org/10.1007/s11999-008-0200-0>)
- 9. Anract P, Biau D & Boudou-Rouquette P.** Metastatic fractures of long limb bones. *Orthopaedics and Traumatology, Surgery and Research* 2017 **103** S41–S51. (<https://doi.org/10.1016/j.otsr.2016.11.001>)
- 10. Tillman R.** Oncological awareness in orthopaedic trauma. *Injury* 2002 **33** 741. ([https://doi.org/10.1016/s0020-1383\(02\)00034-7](https://doi.org/10.1016/s0020-1383(02)00034-7))
- 11. Ma J, Tullius T & Van Ha TG.** Update on preoperative embolization of bone metastases. *Seminars in Interventional Radiology* 2019 **36** 241–248. (<https://doi.org/10.1055/s-0039-1693120>)
- 12. Damron TA, Heiner JP, Freund EM, Damron LA, McCabe R & Vanderby R.** A biomechanical analysis of prophylactic fixation for pathological fractures of the distal third of the humerus. *Journal of Bone and Joint Surgery: American Volume* 1994 **76** 839–847. (<https://doi.org/10.2106/00004623-199406000-00007>)
- 13. Camnasio F, Scotti C, Peretti GM, Fontana F & Frascini G.** Prosthetic joint replacement for long bone metastases: analysis of 154 cases. *Archives of Orthopaedic and Trauma Surgery* 2008 **128** 787–793. (<https://doi.org/10.1007/s00402-007-0464-y>)
- 14. Herrenbruck T, Erickson EW, Damron TA & Heiner J.** Adverse clinical events during cemented long-stem femoral arthroplasty. *Clinical Orthopaedics and Related Research* 2002 **395** 154–163. (<https://doi.org/10.1097/00003086-200202000-00017>)
- 15. Talbot M, Turcotte RE, Isler M, Normadin D, Ianuzzi D & Downer P.** Function and health status in surgically treated bone metastases. *Clinical Orthopaedics and Related Research* 2005 **438** 215–220. (<https://doi.org/10.1097/01.blo.0000170721.07088.2e>)
- 16. Tillman RM, Myers GJ, Abudu AT, Carter SR & Grimer RJ.** The three-pin modified 'Harrington' procedure for advanced metastatic destruction of the acetabulum. *Journal of Bone and Joint Surgery: British Volume* 2008 **90** 84–87. (<https://doi.org/10.1302/0301-620X.90B1.19892>)
- 17. Tillman R, Tsuda Y, Puthiya Veettil M, Young PS, Sree D, Fujiwara T & Abudu A.** The long-term outcomes of modified Harrington procedure using antegrade pins for periacetabular metastasis and haematological diseases. *Bone and Joint Journal* 2019 **101-B** 1557–1562. (<https://doi.org/10.1302/0301-620X.101B12.BJJ-2019-0265.R1>)
- 18. Johnson CN, Gurich RW Jr, Pavey GJ & Thompson MJ.** Contemporary management of appendicular skeletal metastasis by primary tumor type. *Journal of the American Academy of Orthopaedic Surgeons* 2019 **27** 345–355. (<https://doi.org/10.5435/JAAOS-D-17-00749>)
- 19. Coleman RE.** Clinical features of metastatic bone disease and risk of skeletal morbidity. *Clinical Cancer Research* 2006 **12** 6243s–6249s. (<https://doi.org/10.1158/1078-0432.CCR-06-0931>)
- 20. Laitinen M, Parry M, Ratasvuori M, Wedin R, Albergo JI, Jeys L, Abudu A, Carter S, Gaston L, Tillman R, et al.** Survival and complications of skeletal reconstructions after surgical treatment of bony metastatic renal cell carcinoma. *European Journal of Surgical Oncology* 2015 **41** 886–892. (<https://doi.org/10.1016/j.ejso.2015.04.008>)
- 21. Miller BJ, Soni EE, Gibbs CP & Scarborough MT.** Intramedullary nails for long bone metastases: why do they fail? *Orthopedics* 2011 **34** 289–296. (<https://doi.org/10.3928/01477447-20110228-12>)
- 22. Sim FH, Daugherty TW & Ivins JC.** The adjunctive use of methylmethacrylate in fixation of pathological fractures. *Journal of Bone and Joint Surgery: American Volume* 1974 **56** 40–48. (<https://doi.org/10.2106/00004623-197456010-00004>)
- 23. Tillman RM.** The role of the orthopaedic surgeon in metastatic disease of the appendicular skeleton. Working party on metastatic bone disease in breast cancer in the UK. *Journal of Bone and Joint Surgery: British Volume* 1999 **81** 1–2. (<https://doi.org/10.1302/0301-620X.81b1.9514>)
- 24. Kelly CM, Wilkins RM, Eckardt JJ & Ward WG.** Treatment of metastatic disease of the tibia. *Clinical Orthopaedics and Related Research* 2003 415 (Supplement) S219–S229. (<https://doi.org/10.1097/01.blo.0000093843.72468.3a>)
- 25. Biermann JS, Holt GE, Lewis VO, Schwartz HS & Yaszemski MJ.** Metastatic bone disease: diagnosis, evaluation, and treatment. *Journal of Bone and Joint Surgery: American Volume* 2009 **91** 1518–1530.