

## Technical Note

# Arthroscopic Saucerization and Repair of a Torn Medial Discoid Meniscus

Tammam Hanna, M.D., Nathan P. Smith, B.S., and Paul S. Sherbondy, M.D.

**Abstract:** A discoid meniscus is a congenital abnormality that usually affects the lateral meniscus, leading to instability and increased risk of tearing. A discoid medial meniscus is an extremely rare pathology that is seldom described in literature. In this report, we present the technique of operative treatment of a symptomatic, torn discoid medial meniscus. The meniscus is saucerized to 6-8 mm of stable rim, and the inside-out technique is used as the modality of meniscal fixation. Although a discoid medial meniscus is an uncommon finding, all treating surgeons should be aware of the possibility during surgical intervention.

## Introduction

A discoid medial meniscus is an extremely rare congenital abnormality first described by Cave and Staples in 1941.<sup>1</sup> Usually, this pathology involves the lateral meniscus with an overall incidence of 3 to 5%. Currently, fewer than 80 cases of medial discoid meniscus are reported in the literature, according to a review conducted by our team.

We present the technique of arthroscopic saucerization to a stable peripheral rim and repair using an inside-out technique (Video 1). Clinical findings may include medial joint line tenderness, a knee effusion, a positive McMurray's test, a snapping sensation, and pain. Diagnosis is guided by a radiograph and MRI (Fig 1).

## Surgical Technique

### Set Up

The standard room setup for arthroscopy is used. Preoperative examination under anesthesia is performed

to demonstrate intact ligaments, assess knee range of motion, and document additional abnormalities. The surgical procedure is conducted in the standard fashion using supine positioning, a proximal tourniquet, and a lateral post to stress the knee in valgus. The surgical incision sites are marked for the inside-out repair to prevent knee landmark distortion after fluid insufflation (Fig 2). 1% lidocaine with epinephrine is injected into the knee joint, fat pad, and portal sites.

### Diagnostic Knee Arthroscopy

The inferolateral viewing portal and inferomedial working portals are established, through which a diagnostic knee arthroscopy is performed. The use of superior lateral outflow portal is optional and depends on surgeon preference. A hook probe (Smith & Nephew, Andover, MA) is used to confirm a medial discoid meniscus tear. Stability is tested by placing the probe through the tear and pulling the posterior horn anteriorly (Fig 3). At this point, any additional pathology can be diagnosed and addressed, including cartilage defects, symptomatic plicae, and lateral meniscus pathology (Fig 4).

### Saucerization

Saucerization is performed anteriorly to posteriorly using an arthroscopic punch (Smith & Nephew) and shaver (Arthrex, Naples, FL), taking care to leave a 6- to 8-mm stable rim of the meniscus (Fig 5). After saucerization, the tear is re-examined, and meniscus stability is assessed using the probe and by flexing the knee (Fig 6). If visualization of the root is challenging, a 70° scope can be used to perform the Guillquist maneuver to further assess the posterior horn of the medial

*From the Department of Orthopaedics and Rehabilitation, Penn State College of Medicine, The Pennsylvania State University, University Park, Pennsylvania, U.S.A. (T.H., P.S.S.); and Department of Orthopaedics and Rehabilitation, Penn State College of Medicine, Penn State Milton S. Hershey Medical Center, Hershey, Pennsylvania, U.S.A.*

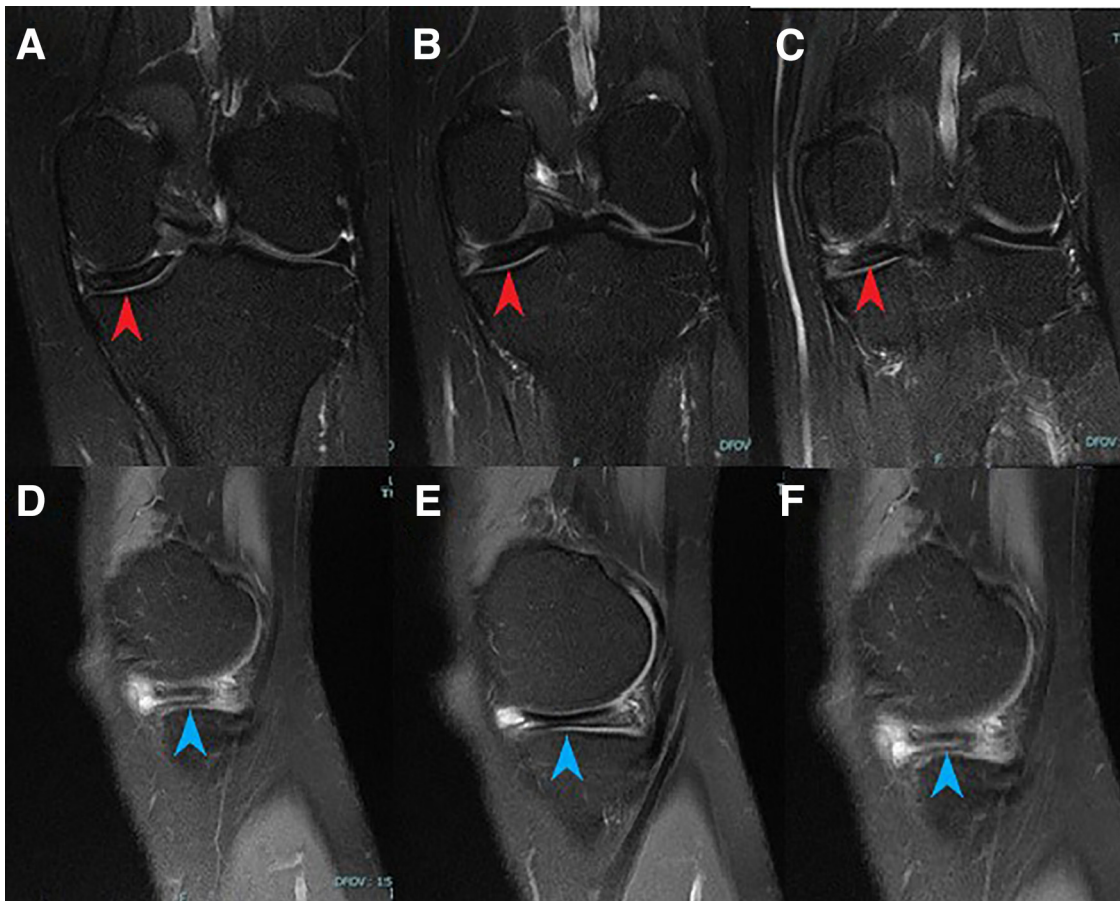
*Received May 11, 2022; revised manuscript received August 16, 2022; accepted September 9, 2022.*

*Address correspondence to Nathan P. Smith, B.S., 187 University Manor East, Hershey, PA, 17033, U.S.A. E-mail: [nsmith15@pennstatehealth.psu.edu](mailto:nsmith15@pennstatehealth.psu.edu)*

© 2022 THE AUTHORS. Published by Elsevier Inc. on behalf of the Arthroscopy Association of North America. This is an open access article under the CC BY-NC-ND license (<http://creativecommons.org/licenses/by-nc-nd/4.0/>).

2212-6287/22639

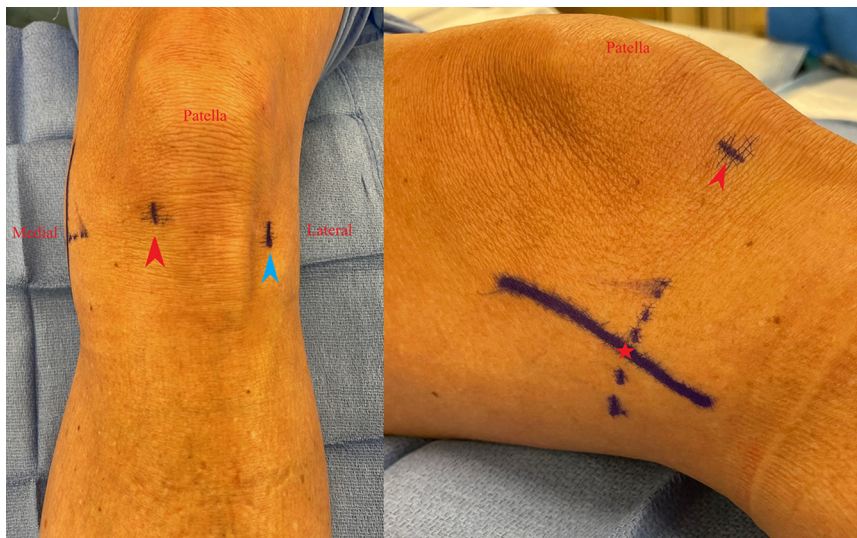<https://doi.org/10.1016/j.eats.2022.09.001>



**Fig 1.** Left knee, preoperative T2 MRI coronal cuts (A-C) demonstrate increased meniscal body width (red arrowheads) and sagittal cuts (D-F) show increased central thickness consistent with discoid meniscus (blue arrowheads).

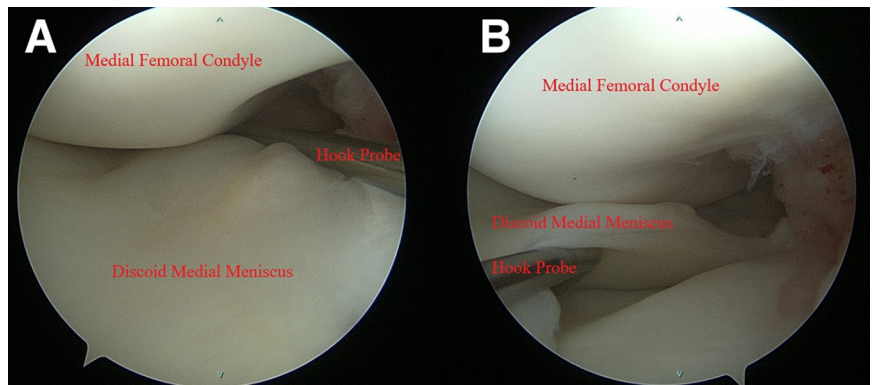
meniscus posteriorly (Fig 7). A meniscal rasp (ConMed Linvatec, Largo, FL) is used to abrade the meniscus on both sides. If there is still difficulty in visualization of the

medial compartment, pie-crusting of the medial collateral ligament is done with an 18-gauge needle percutaneously.



**Fig 2.** Left knee, outside view of arthroscopic incision sites marked prior to fluid insufflation to prevent distortion. The red arrowhead marks the inferomedial portal site, the blue arrowhead marks the inferolateral portal site, and the red star marks the medial incision site.

**Fig 3.** Left knee, arthroscopic view through the inferomedial (A) and inferolateral (B) portals visualizing a left discoid medial meniscus. Stability is tested by placing a hook probe through the tear and pulling the posterior horn anteriorly. Anterior subluxation of the posterior horn is indicative of a meniscocapsular injury.



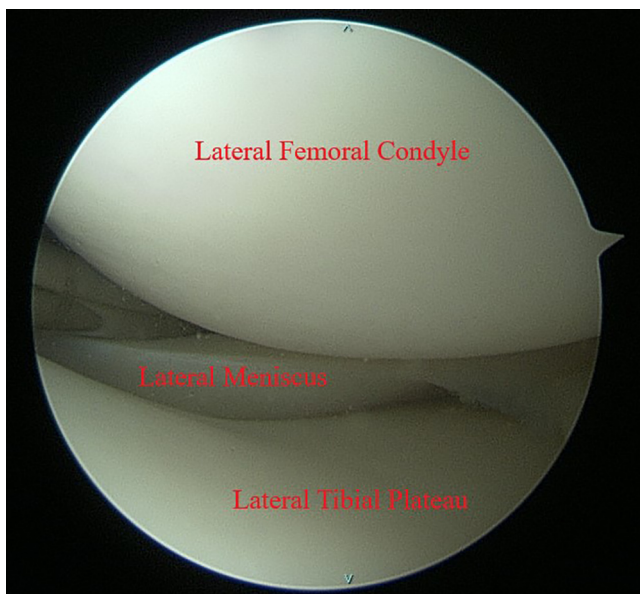
### Meniscus Repair

Anterior subluxation of the posterior horn of the medial meniscus is often due to a meniscocapsular injury. This injury is amenable to repair due to the medial meniscus having a good peripheral blood supply.<sup>2</sup> A standard posterior medial approach for inside-out meniscal repair is performed using the previously marked incision. The skin is dissected to the subcutaneous tissue, the sartorial fascia is identified and divided longitudinally. Then the interval between the joint capsule and the medial head of gastrocnemius is developed. The semimembranosus tendon is identified.

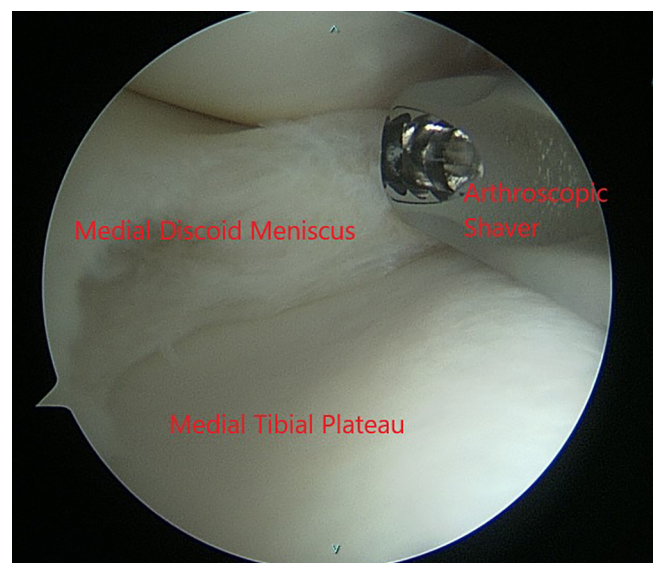
The medial gastrocnemius tendon and muscle are separated from any posterior capsular adhesions using a Cobb elevator. A tablespoon or a similar device (e.g., Graves speculum blade, MedGyn, Addison, IL) can be

placed in this interval to act as a retractor, protecting the popliteal vessels.

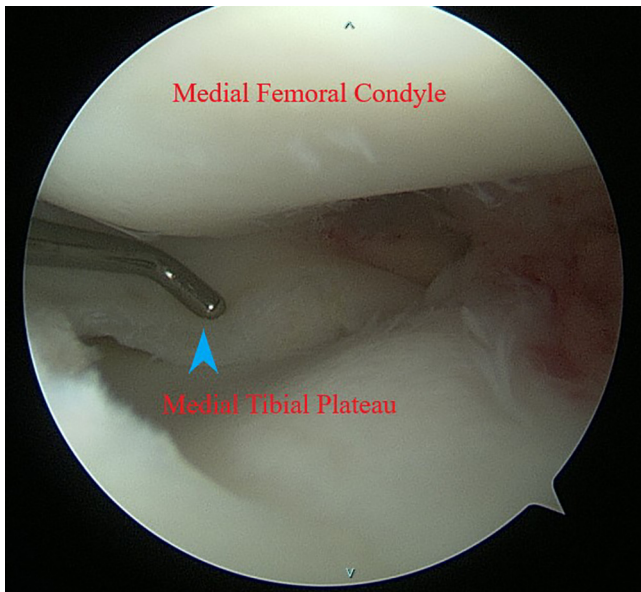
The ZoneNavigator System (Arthrex) is used through the inferolateral portal. Multiple sutures are passed through the meniscal repair needles by the surgical assistant in a vertical mattress fashion. The repair is started posteriorly to secure the meniscus to the posterior capsule and carried on through the meniscal body, as needed (Fig 8). The suture needles are retrieved under direct visualization through the medial incision. After passing all of the sutures through the medial incision, a slight tension is applied and arthroscopic examination of the subluxating meniscus is performed. At this point, the absence of subluxation should be noted. The sutures then can be tied over the capsule. A microfracture awl is used in the notch to



**Fig 4.** Left knee, arthroscopic view through the inferolateral portal. The lateral meniscus is visualized during the diagnostic arthroscopy to assess for any additional pathologies that need to be addressed.



**Fig 5.** Left knee, arthroscopic view through the inferomedial portal. The discoid medial meniscus is saucerized to 6-8 mm of stable rim using an arthroscopic punch and shaver.

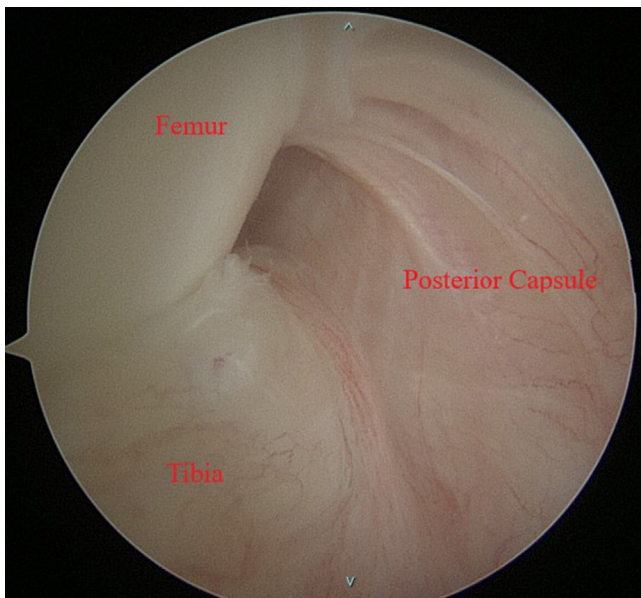


**Fig 6.** Left knee, arthroscopic view of the saucerized medial discoid meniscus through the inferolateral portal. A hook probe (blue arrowhead) is used to assess for meniscal stability after saucerization is complete.

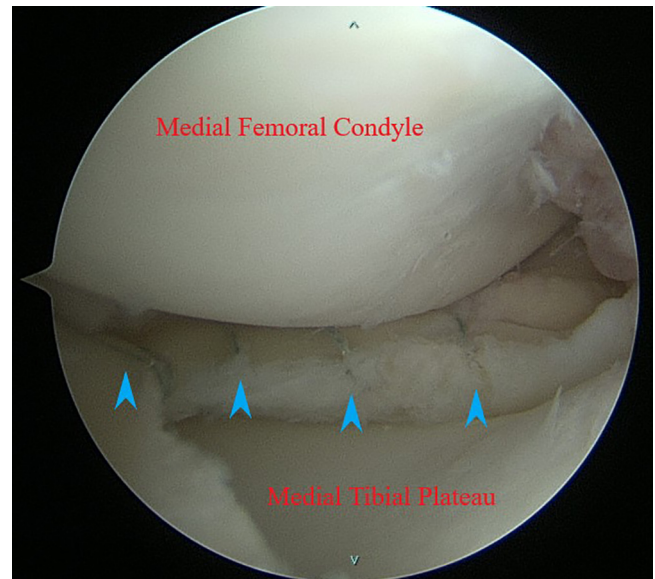
release bone marrow and further induce healing. Incision and portals are closed in the standard surgical fashion. [Table 1](#) discusses pearls and pitfalls of this procedure.

#### Post-Op

A knee immobilizer locked in extension is applied. Partial weight-bearing protocol in the immediate post-operative period (2 weeks) is used. Subsequent



**Fig 7.** Left knee, arthroscopic view through the inferolateral portal using a 70° scope. The Guillquist maneuver can be used to better visualize the posterior horn of the medial discoid meniscus through the notch to assess meniscocapsular injury.

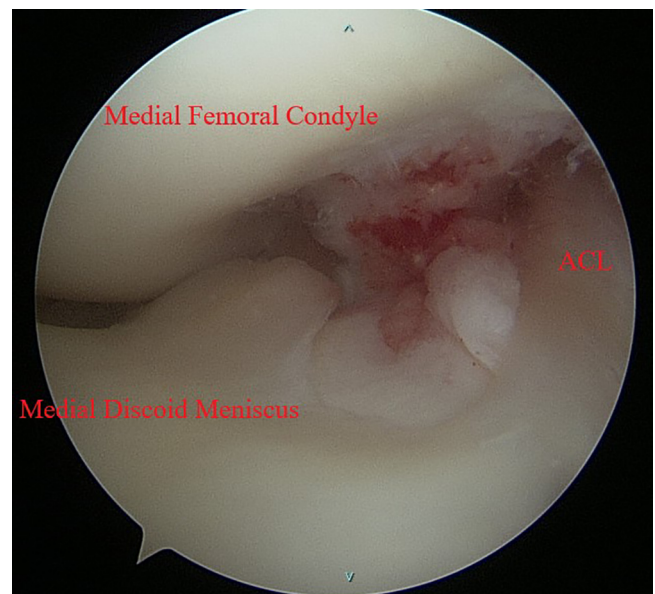


**Fig 8.** Left knee, arthroscopic view through the inferolateral portal. Vertical mattress sutures are placed posteriorly to secure the meniscus to the posterior capsule and carried on through the meniscal body as needed (blue arrowheads). Absence of subluxation of the meniscus should be noted upon completion of the repair.

graduated gentle range of motion is carried on under the supervision of the treating orthopedic surgeon and physical therapist.

#### Discussion

A medial discoid meniscus is a rare pathology, with few cases reported in the literature.



**Fig 9.** Left knee, arthroscopic view through the inferolateral portal. An anomalous insertion of the discoid medial meniscus anterior horn on the anterior cruciate ligament.

**Table 1.** Pearls and Pitfalls of Arthroscopic Saucerization and Inside-Out Repair of a Torn Discoid Medial Meniscus

Pearls	Pitfalls
<ul style="list-style-type: none"> <li>• Frequent intraoperative physical examination can help assess the optimal extent of saucerization.</li> <li>• Liberal use of a 70° scope to improve visualization of root tears.</li> <li>• Use a spoon or speculum to protect vulnerable structures.</li> <li>• Assess the tension of sutures after passing them and before tying knots, failure to do so may cause tight or loose knots.</li> <li>• Consider pie-crusting the medial collateral ligament with an 18-gauge needle if facing problems with visualization of the medial compartment.</li> </ul>	<ul style="list-style-type: none"> <li>• Starting the saucerization procedure without a complete understanding of the pathoanatomy may lead to missed tears, and subsequent oversaucerization.</li> <li>• Failure to establish the medial incision early might lead to erroneous incision due to joint edema later on in the case.</li> </ul>

It is recommended that the discoid meniscus be preserved if no severe symptoms are present.<sup>3</sup> However, a torn medial discoid meniscus can be associated with medial joint line tenderness, severe discomfort from a snapping meniscus, and interference with activities of daily living. Other symptoms reported include locking of the knee, pain in flexion and extension, effusion, positive McMurray's test, and reduced range of motion.<sup>4,5</sup> Repairing a torn posterior horn is important, given its role as a secondary stabilizer, as well as to protect the cartilage.<sup>6</sup> A medial discoid meniscus may have its anterior horn anomalously inserted on the anterior cruciate ligament (Fig 9). The anterior horn insertion at the ACL can be neglected in accordance with previous literature.<sup>7</sup>

Historically, most symptomatic discoid menisci have been treated with partial meniscectomies with attempts to preserve as much as possible of the meniscus to reduce the rate of degenerative changes.<sup>4</sup> However, a recent article by Ahn et al. described 23 pediatric patients with discoid lateral meniscal tears with peripheral instability that were treated with saucerization and meniscal peripheral repair. The technique demonstrated positive results at a mean 51 months follow-up.<sup>8</sup> Although medial and lateral discoid menisci are structurally and biomechanically different, success with saucerization of lateral discoid menisci has been extrapolated to medial menisci with good results. Desai et al. describe treatment of a medial discoid meniscus tear in an 18-year-old male with saucerization and meniscus repair, reporting the patient was asymptomatic at 6 months and 1 year follow-ups and returned to full physical activity.<sup>9</sup> Jin et al. describe saucerization of a symptomatic discoid medial meniscus coalesced with

the anterior cruciate ligament in a 29-year-old male, resulting in no symptoms and full return to physical activities at 12 months.<sup>10</sup> Sevillano-Perez et al. describe treatment of bilateral medial discoid meniscus tears in a 13-year-old football player with saucerization and inside-out repair, resulting in return to preinjury activity level and no symptoms at 2-year follow up.<sup>11</sup> Case reports by Farlett and Wood, Lukas et al., and Iorio et al. show good outcomes at 4-7-month follow-up in pediatric patients undergoing saucerization of medial discoid menisci.<sup>12-14</sup> Finally, Feroe et al. describe 11 saucerized discoid medial menisci in 8 pediatric and adolescent patients with a mean follow-up of 19.1 months. Concomitant meniscal repair was performed in 7 cases. Four cases sustained retears and 1 developed arthrofibrosis, while all other patients were asymptomatic at final follow-up.<sup>5</sup>

Ultimately, recent literature shows some promising outcomes for this technique; however, there is a dearth of literature that analyzes long-term outcomes. Still, advantages of saucerization of a medial discoid meniscus include a meniscus-preserving, reproducible technique that requires standard equipment and operative setup (Table 2).

We prefer the inside-out technique as the modality of fixation for a concomitant meniscal tear, since it is still considered the gold standard for treating these tears. This technique allows for direct visualization of sutures tied over the capsule, but it requires a relatively large medial incision. It is associated with decreased implant cost compared to the all-inside technique, but also increased operative time and risk for iatrogenic nerve injury.<sup>15,16</sup> In addition, recent reports show no difference in complications and

**Table 2.** Advantages and Disadvantages of Arthroscopic Saucerization and Inside-Out Repair of a Torn Discoid Medial Meniscus

Advantages	Disadvantages
<ul style="list-style-type: none"> <li>• Reproducible technique, no need for special equipment or settings, nor a set of new skills</li> <li>• Use of inside out technique is safe, with direct visualization of sutures being tied with appropriate tension over the capsule.</li> <li>• Meniscus-saving procedure</li> <li>• Decreased cost of materials for inside-out repair in comparison to all inside technique</li> </ul>	<ul style="list-style-type: none"> <li>• Dearth of literature with long-term follow up of medial meniscus saucerization</li> <li>• The need for relatively large incision</li> <li>• Increased risk of injury of the saphenous structures posteromedially</li> <li>• Increased operative time in comparison with all-inside repair</li> </ul>

functional outcomes between the two methods, so either may be an appropriate choice.<sup>15,16</sup>

Although discoid medial meniscus is an uncommon pathology, the treating surgeon should be aware of the possibility when intervening surgically, especially with the presence of a palpable snap, which indicates that the tear is highly likely to be unstable. In these circumstances, saucerization and repair of the meniscus are a treatment option that can be considered.

## References

1. Cave EF, Staples OS. Congenital discoid meniscus. A cause of internal derangement of the knee. *Am J Surg* 1941;54:371-376.
2. Woodmass JM, LaPrade RF, Sgaglione NA, Nakamura N, Krych AJ. Meniscal repair: Reconsidering indications, techniques, and biologic augmentation. *J Bone Joint Surg Am* 2017;99:1222-1231.
3. Kocher MS, Logan CA, Kramer DE. Discoid lateral meniscus in children: Diagnosis, management, and outcomes. *J Am Acad Orthop Surg* 2017;25:736-743.
4. Tachibana Y, Yamazaki Y, Ninomiya S. Discoid medial meniscus. *Arthroscopy* 2003;19:E12-E18.
5. Feroe AG, Hussain ZB, Stupay KL, et al. Surgical management of medial discoid meniscus in pediatric and adolescent patients. *J Pediatr Orthop* 2021;41:e804-e809.
6. Levy IM, Torzilli PA, Warren RF. The effect of medial meniscectomy on anterior-posterior motion of the knee. *J Bone Jt Surg - Ser A* 1982;64:883-888.
7. Atay ÖA, Doral MN, Aydingöz Ü, Leblebicioglu G. Bilateral discoid medial menisci: Association with bone changes in the tibia. *Knee Surg Sport Traumatol Arthrosc* 2001;9:217-220.
8. Ahn JH, Lee SH, Yoo JC, Lee YS, Ha HC. Arthroscopic partial meniscectomy with repair of the peripheral tear for symptomatic discoid lateral meniscus in children: Results of minimum 2 years of follow-up. *Arthroscopy* 2008;24:888-898.
9. Desai B, Warren M, Lavie LG, Nammour M, Waldron S. Arthroscopic saucerization of a symptomatic posterior horn tear in a discoid medial meniscus. *Ochsner J* 2021;21:115-118.
10. Jin G, Xin T, Weng Z, et al. Symptomatic complete discoid medial meniscus completely coalesced with the anterior cruciate ligament: A case report and literature review. *Orthop Surg* 2022;14:2391-2395.
11. Sevillano-Perez E, Espejo-Reina A, Espejo-Reina MJ. Symptomatic bilateral torn discoid medial meniscus treated with saucerization and suture. *Case Rep Orthop* 2016;2016:8487194.
12. Farlett J, Wood JR. Ipsilateral medial and lateral discoid menisci: A rare combination of infrequent anatomic variants. *J Clin Imaging Sci* 2020;10:11.
13. Lukas K, Livock H, Kontio K, Carsen S. Bilateral discoid medial menisci: A case report and review of the literature. *J Am Acad Orthop Surg Glob Res Rev* 2020;4:e20:00069.
14. Iorio R, Viglietta E, Mazza D, Redler A, Pagnotta SM, Ferretti A. Saucerization and suture of symptomatic bilateral medial discoid meniscus in a 13 years old male football player: A case report and literature review. *Orthop Rev (Pavia)* 2022;14:33699.
15. Grant JA, Wilde J, Miller BS, Bedi A. Comparison of inside-out and all-inside techniques for the repair of isolated meniscal tears: A systematic review. *Am J Sports Med* 2018;6, 2325967118779045.
16. Vint H, Quartley M, Robinson JR. All-inside versus inside-out meniscal repair: A systematic review and meta-analysis. *Knee* 2021;28:326-337.